Mechanisms and Routes of Aqueous Humor Drainage

Mark Johnson and Kristine Erickson

It appears that Leber,[1] in 1873, was the first to propose that aqueous humor is not a stagnant fluid but instead passes through a circulatory system that drains through tissues found in the limbus region, or angle of the eye. Injection experiments by Schwalbe[2] and Knies[3] supported the existence of an outflow pathway, and perfusion experiments by Leber[1] and Smith[4] demonstrated a pressure-dependent flow. Lauber,[5] in 1901, showed that blood from the ciliary veins in dogs did not contain as high a concentration of blood cells as blood elsewhere in the animal, and he considered this evidence in favor of Leber's theory. Further support for Leber's contention came from experiments conducted by Seidel[6] who showed that dye injected into the anterior chamber of rabbit eyes entered the episcleral veins. Ascher's[7] discovery of the vessels on the surface of the eye that contained a transparent fluid, and Goldmann's[8] finding that these aqueous veins contained aqueous humor, proved Leber's contention beyond the shadow of a doubt (for a more detailed historical review, see Tripathi[9]).

Early histologic studies[9] of the drainage region demonstrated the now familiar structures of trabecular meshwork and Schlemm's canal that drained the aqueous humor into aqueous veins (Fig. 193–34). Ashton[10] used casting techniques to show that neoprene injected into the aqueous veins filled a systems of collecting vessels that originated at Schlemm's canal. More recently, Ujiie and Bill[11] used a low-viscosity cast material to demonstrate that Schlemm's canal, the collector channels and aqueous veins, and the episcleral veins could also be filled from the anterior chamber (Fig. 193–35).

Studies have also indicated that alternate routes exist by which aqueous humor exits the eye.[12] Confirmation of the existence of an unconventional outflow pathway was provided by Bill[13, 14, 16] and Bill and Hellsing.[15] Although an iridial, a corneal, and a retinal outflow pathway have been postulated,[17, 18] the primary unconventional pathway originates at the angle of the eye, passes through the ciliary body and ciliary muscle, enters the supraciliary and suprachoroidal spaces, and finally passes through the sclera into the episcleral tissue[19–21] or is reabsorbed by the vortex veins.[22, 23] The unconventional outflow accounts for a large part of the aqueous outflow in the monkey (as much as 50%),[21] whereas this outflow is much less, perhaps only 10% of the total outflow, in the human eye.[20]

In this chapter, we deal mainly with aqueous humor drainage in humans and primates, although we also note significant difference in other species.

Conventional Outflow Pathway

The aqueous outflow system in the human eye is comprised of the trabecular meshwork, Schlemm's canal, and the aqueous veins (see Fig. 193–34). The trabecular meshwork includes the more superficial uveal meshwork, the deeper corneoscleral meshwork, and the juxtacanalicular connective tissue (JCT) adjacent to Schlemm's canal. Schlemm's canal includes its inner wall endothelium through which the aqueous humor must pass, the canal lumen, and the collector channel ostia by which the canal connects to the aqueous veins that carry the aqueous humor to the episcleral veins on the surface of the eye.

THE TRABECULAR MESHWORK

(See also Chapter 194, Cellular Mechanisms in the Trabecular Meshwork Affecting the Aqueous Humor Outflow Pathway)

There is little filtration of aqueous humor through the most anterior aspects of the uveal and corneoscleral meshwork, since they lie anterior to Schlemm's canal. The uveal meshwork consists of irregular netlike structures with cords that attach to one another in several layers (Fig. 193–36). There are occasional processes originating from the periphery of the iris that merge into this layer. The spaces between the uveal cord are large in the inner aspects of the uveal meshwork and tend to become somewhat smaller in subsequent layers. The number and size of these openings are such that the uveal meshwork can be expected to create negligible resistance to flow, a finding experimentally confirmed by Grant.[24]

The corneoscleral meshwork extends approximately 100 μm in the direction of flow and consists of several interconnecting sheets extending from the scleral spur to the inner aspects of the peripheral cornea (see Fig. 193–34). The openings through which fluid passes this region decrease in size as the deeper aspects of the meshwork are approached. Since the openings do not superimpose in the succeeding layers, the aqueous humor travels a tortuous path as it traverses the meshwork. The structure of this region is similar to that of a well-designed filter. Figure 193–37 shows the corneoscleral meshwork exposed by removing the ciliary muscle.

The JCT, also called the *endothelial meshwork* or *cribriform region,* is the area that follows the last trabecular beam and extends to the inner wall of Schlemm's canal (Fig. 193–38). This region appears to have been first identified by Holmberg[25] who described it as a narrow space between the two endothelial linings of Schlemm's canal, one facing Schlemm's canal and one facing the intertrabecular spaces. The former lining is, of course, now recognized as the endothelial lining of Schlemm's canal, whereas the latter is a discontinuous layer that is more apparent in eyes fixed by immersion than those fixed with a positive intraocular pressure.

The JCT is less ordered than is the corneoscleral meshwork, and its thickness varies between 5 and 10 μm.[26] It appears as a loose connective tissue with relatively free cells attached by processes to one another, to the cells of the inner wall of Schlemm's canal, and to the fine collagen and

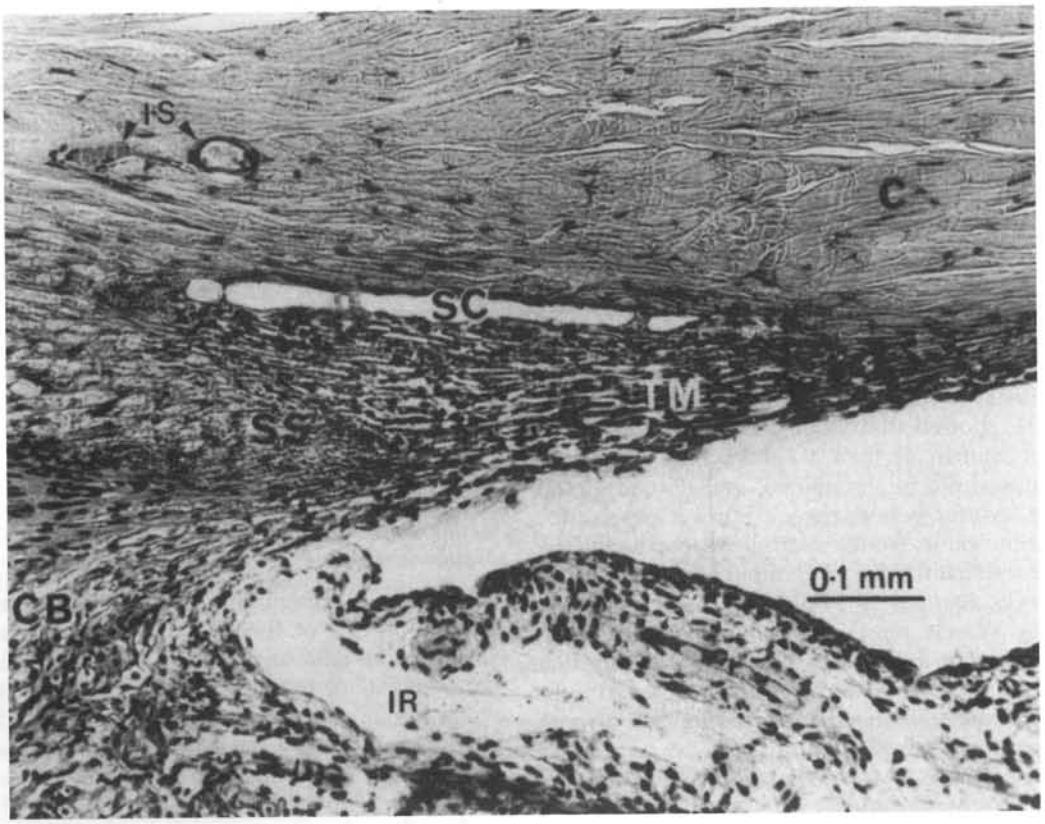

FIGURE 193–34. Light micrograph of the aqueous outflow pathway of a human eye. The aqueous outflow pathway consists of the trabecular meshwork (TM), Schlemm's canal (SC), and the intrascleral collector channels (IS). The TM, located in the inner limbus, extends from the scleral spur (SS), anterior face of the ciliary body (CB), and iris root (IR) to the deeper corneal lamellae (C) and peripheral termination of Descemet's membrane. (From Tripathi RC: The functional morphology of the outflow systems of ocular and cerebrospinal fluids. Exp Eye Res 25[Suppl]:65–116, 1997.)

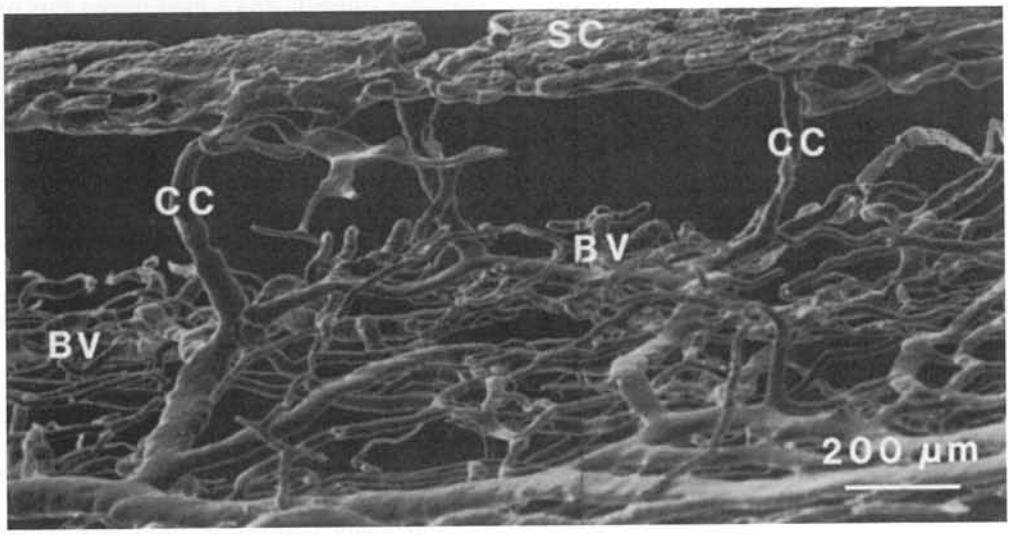

FIGURE 193–35. The anterior chamber of a monkey eye was perfused with Mercox–methyl methacrylate. Scanning electron micrograph of casting material filling Schlemm's canal (SC), collector channels (CC), and intrascleral blood vessels (BV).

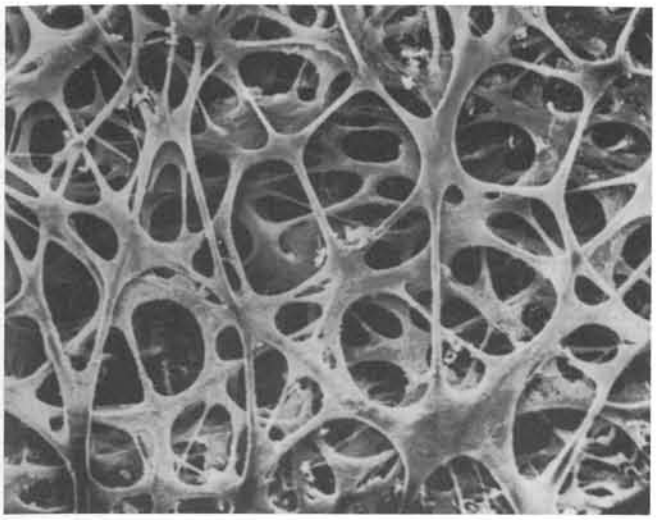

FIGURE 193–36. Scanning electron micrograph demonstrates the appearance of the uveal meshwork as viewed from the anterior chamber. ×504. (Freddo TF, Pallerson MM, Scott DR, Epstein DL: Influence of mercurial sulfhydryl agents on aqueous outflow pathways in enucleated eyes. Invest Ophthalmol Vis Sci 25:278–285, 1984. © Association for Research in Vision and Ophthalmology.)

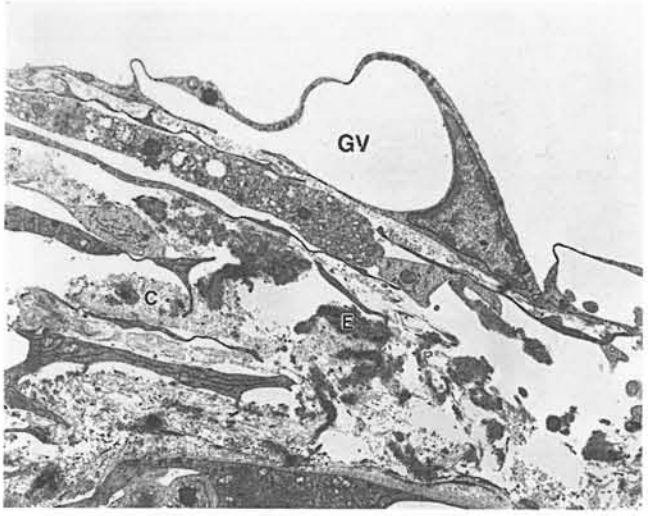

FIGURE 193–38. Transmission electron micrograph of the juxtacanalicular connective tissue (JCT) in a human eye fixed at an intraocular pressure (IOP) of 15 mm Hg. Note the collagen (C) and elastin (E) in the JCT and the giant vacuoles (GV) in the inner wall endothelium of Schlemm's canal. (Courtesy of Haiyan Gong, M.D., Ph.D.)

elastic fibrils and fibers found in this region. These cells are different from those of the inner wall of Schlemm's canal, having instead a fibroblastic appearance and lacking a basal lamina.[27] A ground substance whose composition includes glycosaminoglycans and type IV and VI collagen[27] is present in parts of this region, as is a material identified as plaque[28, 212] (Fig. 193–39). Experimental findings described further on indicate that, at least in normal monkey eyes, the main resistance to aqueous outflow is located in this region.

Tendon-like extensions from the ciliary muscle pass through this region[29] and are likely responsible for the effects of ciliary muscle contraction on outflow facility (Fig. 193–40).[30]

The trabecular meshwork cells covering the corneoscleral and uveal trabecular beams likely have as one of their roles the maintenance of normal outflow resistance. To accomplish this function, debris that enters the meshwork (e.g., pigment lost from the iris) is engulfed by these cells and then phagocytosed. It has been observed that after phagocytosis these cells can carry the ingested material out of the eye.[31] Thus the trabecular meshwork and, for that matter, the JCT region



FIGURE 193–37. Scanning electron micrograph of the innermost part of the corneoscleral portion of the trabecular meshwork in a human eye. The meshwork was exposed by stripping the ciliary muscle and the attached uveal meshwork from the preparation. O, openings in the meshwork; U, remains of uveal meshwork.

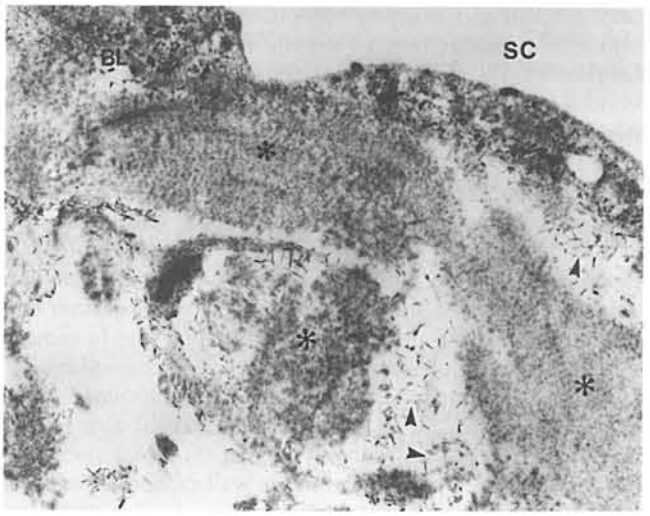

FIGURE 193–39. Transmission electron micrograph of the juxtacanalicular connective tissue in a human eye prepared using staining with cuprolinic blue to demonstrate sulfated proteoglycans (stick figures seen in micrograph). Proteoglycans are associated with basal lamina (BL) of the endothelial cells of Schlemm's canal (SC) and collagen fibrils *(arrowheads)* but not with "plaque" material *(asterisks)*. (Courtesy of Haiyan Gong, M.D., Ph.D.)

FIGURE 193–40. Light micrograph of tangential section through the trabecular meshwork of a human eye showing ciliary muscle (CM) tendons passing into the corneoscleral meshwork and entering the cornea (C). (From Rohen JW, Futa R, Lütjen-Drecoll E: The fine structure of the cribriform meshwork in normal and glaucomatous eye as seen in tangential sections. Invest Ophthalmol Vis Sci 21:574–585, 1981.)

might be described as self-cleaning filters of progressively smaller size placed in front of the inner wall endothelium.

Filtration studies using microspheres support this view.[32] In human eyes studied in vitro, approximately 50% of 0.18-μm particles were caught in the trabecular meshwork and especially in the JCT tissue when perfused through this region. After fixation of the outflow routes with glutaraldehyde, capture of these small microspheres was greatly enhanced.[33] Bill and Mäepea[34] speculated that flexibility of the extracellular matrix may be crucial for the passage of particles through the JCT region. After fixation, the matrix might become immobilized owing to cross-linking so that particulates could no longer easily pass through this region. Bill further speculated that with increasing age, increased cross-linking may occur as part of the process, leading to accumulation of extracellular material in the JCT tissue, increased outflow resistance, and ultimately to the development of glaucoma. However, morphologic evidence for such an accumulation, sufficient to generate a significant outflow resistance, is lacking.[110, 112, 212]

INNER WALL ENDOTHELIUM OF SCHLEMM'S CANAL

The endothelial lining of the inner wall of Schlemm's canal (Fig. 193–41) is a continuous layer of elongated cells attached to one another by tight junctions and lying on a discontinuous basement membrane.[27] The cells are generally oriented parallel to the direction of flow in the canal.

The mechanism by which fluid crosses this endothelium has been debated for more than a century. Schwalbe[2] and Leber[1] had a lively debate as to whether open communication existed between the anterior chamber and Schlemm's canal; Leber contended that no pores existed and that the aqueous humor must pass through an intact membrane, whereas Schwalbe insisted that there were pores in this membrane. Seidel[6, 35] confirmed Schwalbe's results showing open communication and came to the conclusion that pores not visible at the light microscopic level must pass through the inner wall endothelium. Only with the advent of the electron microscope could Seidel's conclusion be verified.

Garron and colleagues,[36] Holmberg,[25] and Speakman[37] first described the appearance of the inner wall endothelium using the electron microscope. They described an apparently unique feature of many of these inner wall cells, namely, the large or giant vacuoles that appear to be within the cells (Fig. 193–42). These structures (2 to 6 μm in diameter and as long as 25 μm) are not true intracellular structures. Instead, serial sections have demonstrated that all the giant vacuoles have an opening on their basal side and therefore would appear to be outpouchings or invaginations of the cell, extending from the trabecular meshwork side into the canal, caused by the pressure drop across the inner wall endothelium (Figs. 193–43 and 193–44).[33]

Tripathi[38] suggested that the giant vacuoles might be transient structures and proposed a process by which vacuolar formation might occur as a cyclic process. Current thought indicates that these structures form passively as a result of the pressure drop across the inner wall endothelium, since the number of these vacuoles have been observed to increase as the intraocular pressure (IOP) is increased.[39, 40] This fact makes it important that enucleated eyes are perfused when

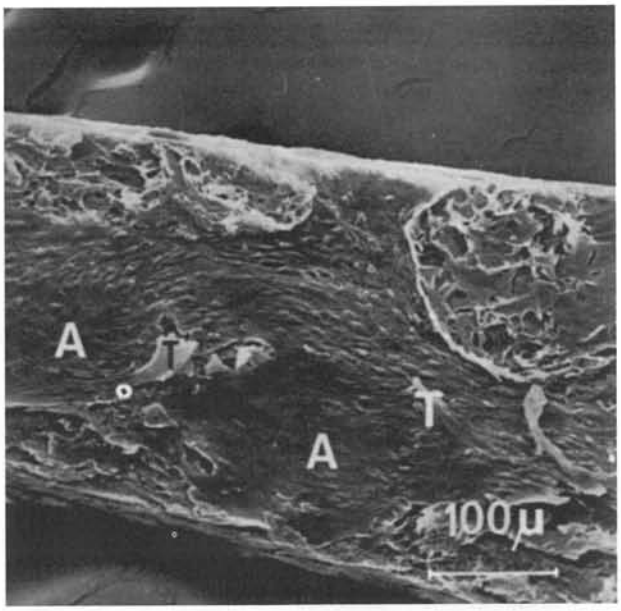

FIGURE 193–41. Scanning electron micrograph of the inner wall of Schlemm's canal in a human eye. Several tissue strands (T) were broken when the canal was opened, and large parts of the inner wall and adjacent tissue were lost. The intact aspects of the inner wall demonstrated structures about 10 μm in length bulging into the lumen of the canal. These are nuclei of the endothelial cells and associated invaginations. The orientation of the bulging structures suggests a preferential flow in the canal. At point A, there are few bulging structures, suggesting that these are regions with little drainage of aqueous humor.

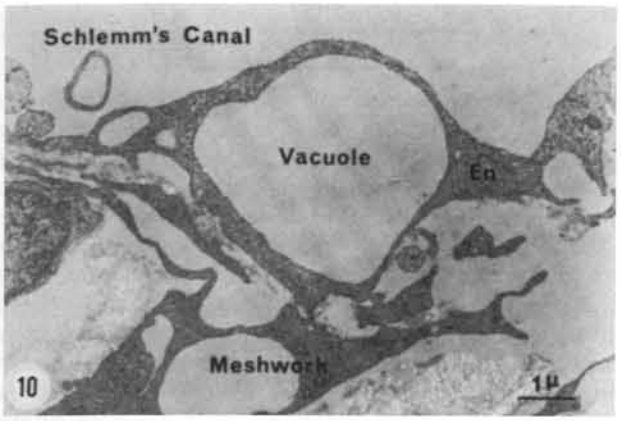

FIGURE 193–42. Transmission electron micrograph of the inner wall of Schlemm's canal and the adjacent subendothelial tissue showing empty spaces or "giant vacuoles" within the endothelial cells. (From Inomata H, Bill A, Smelser GK: Aqueous humor pathways through the trabecular meshwork and into Schlemm's canal in the cynomolgus monkey *[Macaca irus]:* An electron microscopic study. Am J Ophthalmol 73:760, 1972.)

they are fixed for morphologic examination so that a natural pressure drop is present across the endothelium.

The wall of the invaginations tended to be very thin in places, and in such regions, pores, as postulated by Schwalbe and Seidel, were seen to form (see Fig. 193–43), apparently allowing fluid to pass into Schlemm's canal. It is interesting that these pores do not necessarily overlap with the vacuolar opening on the meshwork side. And although most pores are associated with the giant vacuoles, a few pores can also be found in thin, flat regions in the inner wall.[33] The pores usually range in size from 0.1 μm to greater than 3 μm, with an average diameter of just less than 1 μm.[41] It is

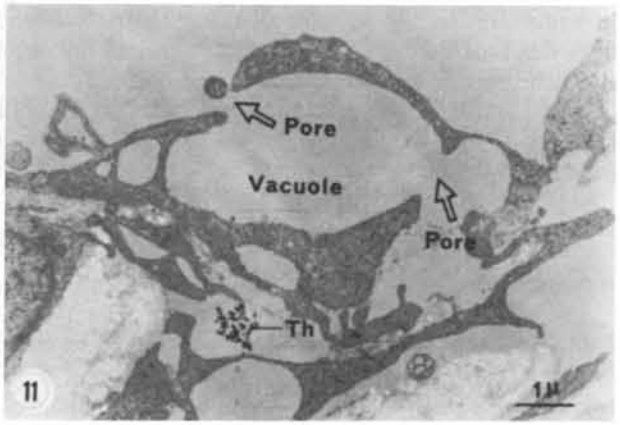

FIGURE 193–43. Transmission electron micrograph of the inner wall of Schlemm's canal in a monkey eye. Serial sections of the inner wall of Schlemm's canal indicate that the "giant vacuoles" of the endothelial cells have openings toward the trabecular side, indicating that they are invaginations from the trabecular side. Some of the invaginations also have openings (pores) into Schlemm's canal. Aqueous humor can pass through the cells via the invaginations and the pres. Th, Thorotrast. (From Inomata H, Bill A, Smelser GK: Aqueous humor pathways through the trabecular meshwork and into Schlemm's canal in the cynomolgus monkey *[Macaca irus]:* An electron microscopic study. Am J Ophthalmol 73:760, 1972.)

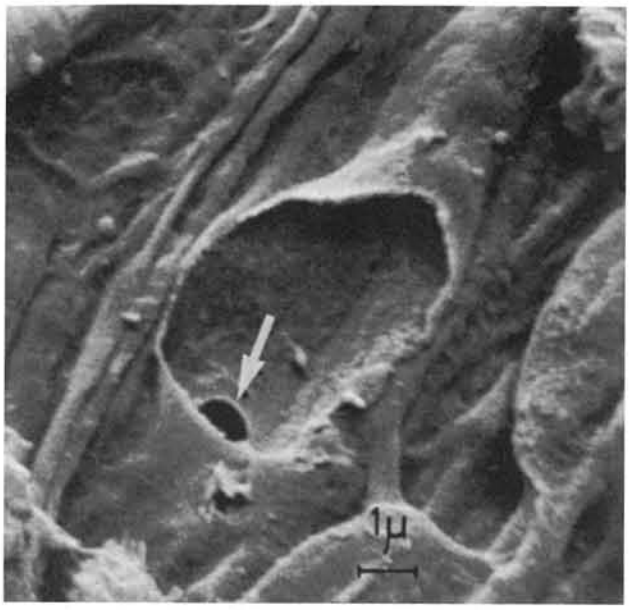

FIGURE 193–44. Scanning electron micrograph of the inner wall of Schlemm's canal in a monkey. The opening *(arrow)* from the trabecular side into an invagination can be observed through a break in the wall of the invagination. (From Bill A: Scanning electron microscopic studies of the canal of Schlemm. Exp Eye Res 10:214, 1970.)

important to note that this size range is consistent with the pore size predicted by Seidel.[35]

The number of pores in the inner wall have been estimated in a number of studies[40, 42–46] to vary between 1000 and 2000 pores/mm². The number of inner wall cells per mm² of inner wall can be estimated as 2000 to 5000 cells/mm², as the area of these cells has been measured between 200 and 500 μm².[44, 47] Thus, we can conclude that there is roughly 0.2 to 1 pore/cell. Scanning electron microscopy has been used to determine that between 13 and 29% of the vacuoles have pores,[43, 45, 46] which seems consistent with this estimate. The size and number of the pores (about 20,000 in the human eye)[44] were found to be more than sufficient to account for the flow of aqueous humor into Schlemm's canal, and Bill and Svedbergh[44] estimated that these pores generate at most 10% of aqueous outflow resistance.

SCHLEMM'S CANAL, COLLECTOR CHANNELS, AND THE AQUEOUS VEINS

On passing through the inner wall endothelium, the aqueous humor enters Schlemm's canal, which has the appearance of a highly elongated ellipse in cross-section, with the major axis diameter varying between 150 and 350 μm[26] and its minor axis (distance between inner and outer wall) varying between 1 and 30 μm, depending on the IOP.[48] The inner wall endothelium, as viewed from within the canal, has a cobblestone appearance primarily resulting from the giant vacuoles but also from the nuclei of the inner wall cells (see Fig. 193–41).

The outer wall of the canal has no particular distinguishing characteristics except for the occasional collector channels that drain the canal. Occasional vacuolization is seen, but it is not prominent. Throughout the canal, especially near the

collector channels, are septa that connect the inner wall with the outer wall. The proximity of these structures to the collector channels may indicate that their function is to prevent complete collapse of the canal and to prevent occlusion of the collector channels.[49, 50]

After entering the canal, the aqueous humor travels circumferentially around the eye until it reaches one of the 30 or so collector channels that join Schlemm's canal. The collector channels are tens of microns in diameter.[9, 51–53] Fluid flows from the collecting channels into the aqueous veins that ultimately drain into the episcleral venous system.

Unconventional Outflow Pathway

Because the interstitial spaces of the anterior uvea are in direct contact with the fluid in the anterior chamber and in the intertrabecular spaces (Fig. 193–45), a fraction of the aqueous humor outflow that passes through the uveal meshwork can enter the interstitial spaces of the ciliary body. Perfusion studies with microspheres[54] have demonstrated that flow passes from this region through the spaces between the muscle bundles of the longitudinal part of the ciliary body and enters the supraciliary and suprachoroidal spaces (see Fig. 193–45). When the fluid reaches the sclera, the microspheres are trapped because the sclera restricts even 10-nm Thorotrast particles from entering.[54]

FIGURE 193–45. Meridional section through the uveal tract of a *Macaca fascicularis*. *Arrowheads* show supraciliary and suprachoroidal space. Unconventional outflow passes from the anterior chamber (AC), through the most posterior aspects of the uveal meshwork, through the open spaces between the longitudinal part of the ciliary muscle, and enters the supraciliary and suprachoroidal spaces. SC = Schlemm's canal; PP = pars plana. (From Wood RL, Koseki T, Kelly DE: Structural analysis of potential barriers to bulk-flow exchanges between uvea and sclera in eyes of Macaque monkeys. Cell Tissue Res 260:459–468 [Fig. 1a], 1990. By permission of Springer-Verlag.)

There is some debate about where the fluid passes from here. Bill[19, 21] and Bill and Phillips[20] and more recently Gabelt and Kaufman[55] thought that the fluid seeps through the sclera and episclera, passes into the orbit, and then is absorbed by the blood vessels there. In contrast, others[22, 23] postulated that the fluid is absorbed osmotically by the vortex veins. We address the evidence for each of these propositions later in this chapter.

Nevertheless, it appears that there exists a communication of aqueous humor all the way from the anterior chamber, through the ciliary muscle and suprachoroidal spaces, entering the posterior sclera. The ciliary muscle likely represents a significant site of flow resistance along this pathway. Pilocarpine, which causes ciliary muscle contraction and thereby decreases the size of spaces between the muscle bundles, decreases outflow through this unconventional outflow pathway, whereas atropine, a muscaranic antagonist, does the converse.[56] Furthermore, $PGF_{2\alpha}$, recently shown to increase unconventional outflow, is thought to act by decreasing the extracellular matrix between ciliary muscle bundles.[57] Rohen (personal communication) has speculated that the decreased unconventional outflow in the human eye as compared with the primate eye is due to further evolutionary development of the ciliary muscle in the human.

Generation of Intraocular Pressure

Aqueous humor passes from the anterior chamber through the outflow pathway as a bulk flow driven by a pressure gradient. Studies have indicated that neither metabolic poisons[58] nor temperature (outside of the effect on viscosity)[59] affects this bulk flow, and thus this system does not involve active transport. Under steady-state conditions, the aqueous inflow (F) must be equal to the sum of the conventional outflow (F_{TM}) and the unconventional outflow (F_u). Outflow facility (C) is defined as the ratio of the conventional outflow to the pressure drop driving this flow: $IOP - P_v$, where P_v is the episcleral venous pressure. We then find that:

$$F = C(IOP - P_v) + F_u \qquad \text{(Eq. 1)}$$

Alternatively, one can write that:

$$IOP = R(F - Fu) + P_v \qquad \text{(Eq. 2)}$$

where the outflow resistance is $R = 1/C$. Equation 2 shows that the pressure in the anterior chamber is increased by increasing R, F, or P_v, and decreased by increasing F_u; the latter conclusion is a direct result of the assumption that unconventional outflow is pressure-independent, an assumption we discuss later. Note that if this assumption is not correct, the measurements of outflow facility, described further on, will include a contribution from the unconventional outflow.

INFLUENCE OF INTRAOCULAR PRESSURE ON OUTFLOW PARAMETERS

Although Equation 2 shows how changes in outflow parameters can influence IOP, it is important to realize that several of these parameters are themselves functions of IOP. In particular, outflow facility is not quite a constant but decreases with increasing IOP (2% per mm Hg[60]). This is thought to be due to collapse of Schlemm's canal as IOP is increased, since this decrease is not observed when Schlemm's canal collapse is inhibited by depression of the lens in enucleated eyes[61] (lens depression acts in a manner similar to pilocarpine, pulling on the outflow pathway and opening the canal).

Another important effect is that of IOP on the aqueous inflow rate. This is termed *pseudofacility* and results because an increase in IOP leads to a decrease in the aqueous inflow rate. Bill[62] measured pseudofacility in the live primate to be approximately 0.01 to 0.02 μL/min/mm Hg, or approximately 0.5 to 1% per mm Hg for an inflow rate of 2 μL/min. This phenomenon is thought to result from a decreased ultrafiltration, although aqueous humor formation is thought to be primarily a secretory process (see first part of this chapter).

Unconventional outflow is usually assumed to be pressure-independent. However, Pederson and colleagues[22] and Pederson and Toris[63] found this flow to be pressure-dependent. Furthermore, even Bill's original report[19] on the pressure independence of unconventional outflow showed some pressure dependence. Perhaps this flow is better described as pressure-insensitive. The assumption of a pressure-independent unconventional outflow can lead to a significant error when trying to deduce this flow by measuring IOP, inflow, and outflow facility and then calculating unconventional outflow from Equation 1 such as in the approach described by Yablonski and associates.[64] This error is compounded by the pressure dependence of the other parameters in Equation 1, especially *C*.

Finally, episcleral venous pressure is also somewhat influenced by IOP, although this effect is apparently rather small.[65] In these studies, episcleral venous pressure was measured using a micropuncture technique, although other techniques for clinical measurement of episcleral venous pressure have also been described with similar results.[66]

Outflow Facility/Resistance

Glaucoma is strongly associated with increased IOP and this increased IOP is caused by a decreased outflow facility, or equivalently, an increased outflow resistance (Fig. 193–46).[1, 67] Because of this, there has been great interest in determining where in the outflow pathway the bulk of aqueous outflow resistance is generated in a normal eye and how this resistance is altered in primary open-angle glaucoma.

MEASUREMENT OF OUTFLOW FACILITY

Under experimental conditions, outflow facility is normally determined by perfusing the eye under conditions of constant pressure while monitoring the flow entering the eye.[68–70] Constant pressure perfusion is used as opposed to constant flow, as the former has a much shorter time constant for equilibration.[71] Constant pressure perfusion also better maintains the geometry of the outflow pathway closer to its physiologic state, since this geometry is pressure-dependent.[48]

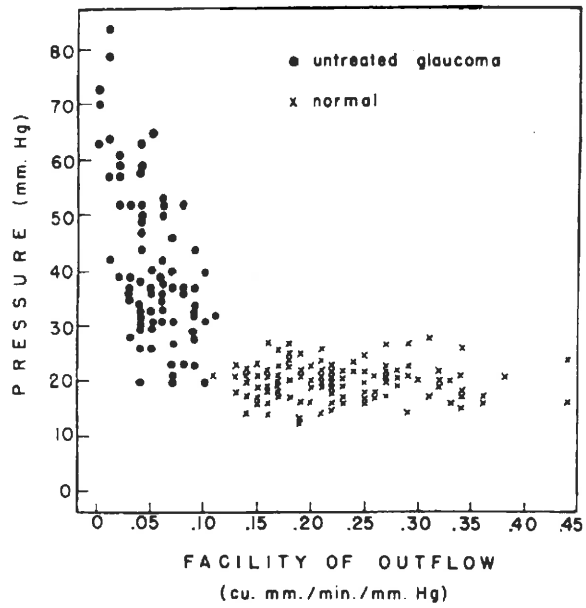

FIGURE 193–46. Comparison of IOP and outflow facility in 118 normal eyes and 75 untreated glaucomatous eyes. (From Grant WM: Clinical measurements of aqueous outflow. Arch Ophthalmol 46:113–131, 1951. Copyright 1951, American Medical Association.)

When determining outflow facility in live animals, the anterior chamber is first cannulated and then, after equilibration, inflow into the eye from an external reservoir is determined at two different pressure levels (one of the levels may be the spontaneously occurring level). It is important that sufficient time be left between pressure changes for the flow to equilibrate to its new steady-state value, as there will be a transient filling curve as the pressure is increased. Using Equation 1, and assuming the other parameters are constant (a reasonable assumption provided that ΔIOP is not too large), we find that:

$$C = \frac{\Delta F}{\Delta IOP} \qquad \text{(Eq. 3)}$$

where ΔF is the change in flow caused by ΔIOP, the change in pressure.

In an enucleated eye, the situation is somewhat simpler as $P_v = 0$, and the spontaneous level is simply that of IOP = F = 0. Then,

$$C = \frac{F}{IOP} \qquad \text{(Eq. 4)}$$

To actually conduct an experimental perfusion in a live animal, after anesthesia a perfusion needle is placed with its tip in the anterior chamber of the eye. In an enucleated eye, the needle tip is placed in the posterior chamber.[72] Alternatively, after corneal trephination an iridotomy is performed, and then a Grant fitting is placed in the trephine, and flow passes into the anterior chamber through this fitting.[73] The additional steps (needle in the posterior cham-

ber or trephination) are necessary in the enucleated eye because without normal flow through the pupil as occurs in a live animal, pupillary block is possible, which then leads to anterior chamber deepening and a greatly increased outflow facility.[74] Flow is then started through the needle or Grant fitting while IOP is monitored. The perfusion fluid is usually buffered saline that includes glucose and calcium.

An alternative way to measure outflow facility in live animals or humans is to change the inflow rate using pharmacologic agents[64, 75] and measure the rate change using fluorophotometric measurements of aqueous flow.[76] By determining the change in pressure caused by a change in flow, Equation 3 can again be used to determine outflow facility. Note again the importance of establishing a steady-state condition.

In humans, outflow facility is also measured using tonography, first described by Grant.[77] This, unlike the previously described methods, is a measurement that is not at steady-state. Briefly, a small weight is placed on the eye, which increases the IOP, and the decay of IOP over time is then monitored. The extent to which pressure decays in 4 minutes is a measure of the outflow facility, since the decay in pressure is caused by flow leaving the eye through the outflow pathway. However, the elasticity of the scleral envelope of the eye also strongly affects this decay constant (the stiffer the eye, the more rapid the decay), and thus the determination of outflow facility by this approach is more complicated than that suggested by Equation 3.[78]

GENERATION OF AQUEOUS OUTFLOW RESISTANCE

As mentioned, one of the central questions involving aqueous humor outflow and glaucoma concerns where in the outflow pathway flow resistance is generated and by what mechanism. The current view is that a majority of the outflow resistance is generated by the extracellular matrix in the JCT, but there is still considerable interest by some investigators[79–81] in the possibility that the inner wall endothelium of Schlemm's canal generates a significant fraction of aqueous outflow resistance. Although there is consensus that the bulk of outflow resistance in the normal eye resides near or within the inner wall of Schlemm's canal in the normal eye, there is not such a consensus about where the increased outflow resistance characteristic of primary open-angle glaucoma (POAG) is localized, although it appears not to reside in the aqueous veins. In this section, we review the evidence leading to these conclusions regarding the localization of outflow resistance in the normal and glaucomatous eye.

Outflow Resistance of the Outer Meshwork

As first shown theoretically by McEwen,[82] the uveal meshwork and corneoscleral meshwork have too many openings of such large size to generate any significant outflow resistance. Using Poiseuille's law, we can find that a single pore 100 μm long (the length of the trabecular meshwork) with a diameter of 20 μm can carry the entire aqueous outflow (2 μL/min) with a pressure drop of 5 mm Hg. Since the trabecular meshwork has numerous openings this large or even larger,[9] it can be concluded that the pressure drop through this region is negligible. Experimental support for this proposition was provided by Grant[24] who cut through the proximal regions of the meshwork and found no effect on outflow facility.

Outflow Resistance of the Aqueous Veins

Similar calculations show that the resistance of the aqueous veins should also be negligible (30 vessels with an average diameter of 50 μm and a length of roughly 1 mm).[83] Here, however, the experimental evidence is not as clear. A number of investigators[24, 73, 84–87] have perfused enucleated primate and human eyes both before and after 360-degree trabeculotomy. This procedure should eliminate all flow resistance except that distal to Schlemm's canal. Surprisingly, these studies have all shown that at least 25% of outflow resistance remains after this procedure, and Rosenquist and colleagues[83] showed that under conditions of a physiologic pressure drop across the outflow pathway (7 mm Hg), 50% of the outflow resistance remains after 360-degree trabeculotomy.

Mäepea and Bill,[65, 88] however, recently came to a different conclusion. Using technology developed for determining pressure in very small blood vessels, they measured the pressure in Schlemm's canal in live monkeys. The pressure values they obtained (similar to episcleral venous pressure and much less than IOP) were in agreement with the hypothesis that little outflow resistance is generated by the aqueous veins (10% or less). This discrepancy between the measured pressure in Schlemm's canal and the effect of trabeculotomy remains unexplained.

Although scientifically important, these findings are diminished in their physiologic significance by the finding of Grant[24] that in the eight enucleated glaucomatous eyes investigated, a trabeculectomy eliminated all the enhanced glaucomatous outflow resistance in these eyes. This result indicated that in these eyes, the obstruction of outflow is proximal to the aqueous veins. This finding is supported by the success of laser trabeculoplasty in reducing outflow resistance in the glaucomatous eye.[89] Although it is unclear how laser trabeculoplasty actually works to lower outflow resistance,[90] it seems unlikely that its action is on the aqueous veins. Thus, although an important scientific question remains regarding the contribution of the aqueous veins to normal outflow resistance, these vessels likely have little involvement in the pathogenesis of POAG.

Outflow Resistance of Schlemm's Canal

Schlemm's canal is a space that exists between the endothelial-lined termination of the trabecular meshwork and the outer wall of Schlemm's canal. Johnstone and Grant[48] showed that as IOP increases, the trabecular meshwork expands, leading to a concomitant narrowing of Schlemm's canal until the canal is largely collapsed when IOP exceeds episcleral venous pressure by roughly 30 mm Hg. Johnstone and Grant pointed out that this is similar to the arrangement of a one-way valve in which the trabecular meshwork closes down as IOP is reduced or, perhaps more importantly, when episcleral venous pressure is increased. This closure inhibits blood reflux. It is also true that the lack of pores and giant vacuoles at low IOP contributes to this barrier function, as

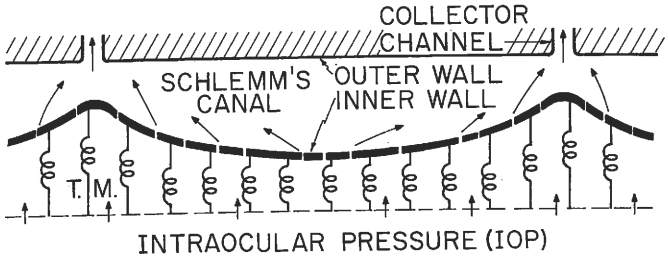

FIGURE 193–47. Schematic model of Schlemm's canal as a porous, compliant channel with the trabecular meshwork (T.M.) modeled as a set of springs holding the canal open while the pressure drop across the inner wall is acting to close the canal. (From Johnson M, Kamm RD: The role of Schlemm's canal in aqueous outflow from the human eye. Invest Ophthalmol Vis Sci 24:320–325.)

does aggregation of platelets during blood reflux at places where the platelets contact subendothelial structures.[91] It is important to note that this one-way valve function of the trabecular meshwork is a direct result of the existence of Schlemm's canal. Without the canal, the trabecular meshwork would be attached to the outer wall of the canal and unable to close down in response to changes in venous pressure.

In its open state, the canal has a minor diameter of roughly 30 μm, too large to generate an appreciable outflow resistance. However, the potential for Schlemm's canal to collapse as IOP is increased has led some investigators to postulate that significant outflow resistance can be generated in its collapsed state. Van Buskirk[61] showed that Schlemm's canal collapse is associated with an increased outflow resistance, and Nesterov[92] postulated that canal collapse could cause the elevated outflow resistance characteristic of POAG.

Several theoretical studies have estimated the outflow resistance of Schlemm's canal.[50, 93, 94] Schlemm's canal was modeled as a porous (the inner wall pores), compliant elliptical channel that directs aqueous humor from the inner wall pores to the nearest collector channels. The trabecular meshwork was modeled as a set of springs that attached to the porous inner wall endothelium and provided the compliance of the canal. Increasing IOP stretched these springs (by increasing the pressure drop across the inner wall) and collapsed the canal (Fig. 193–47).

The conclusion of these studies was that unless the canal was narrowed to roughly 2 μm or less, it would generate little flow resistance. Septa in the canal were found to prevent its complete collapse, which otherwise might greatly increase outflow resistance. Perhaps most significantly, Johnson and Kamm[50] found that glaucoma was unlikely to result from a collapse of Schlemm's canal. They based this conclusion on the finding that in an eye perfused at 50 mm Hg, Schlemm's canal was entirely collapsed,[48] yet the outflow facility at 50 mm Hg[60] is not as low as that of a typical glaucomatous eye. Thus, glaucoma must involve more than just collapse of Schlemm's canal.

It should be noted that although Schlemm's canal collapse likely does not, in and of itself, cause glaucoma, it clearly makes the problem worse. The increased IOP in the glaucomatous eye leads to collapse of the canal, thereby increasing its resistance and exacerbating the problem. Pilocarpine, discussed at greater length later in this chapter, increases ciliary muscle tone and thereby acts to open the canal.[95]

Outflow Resistance of the Inner Wall Endothelium of Schlemm's Canal

As mentioned, the method by which fluid crosses the inner wall endothelium has puzzled investigators since the outflow pathway was first identified. To understand the flow resistance generated by this structure, it must first be recognized that this endothelium appears to have the highest hydraulic conductivity of any endothelium in the body. The hydraulic conductivity (L_p) is defined as:[96]

$$L_p = \frac{F/A}{\Delta P} \qquad \text{(Eq. 5)}$$

where F/A is the flow per unit area crossing the endothelium and ΔP is the pressure drop across the endothelium. Table 193–4 shows the hydraulic conductivity of a number of different endothelia, including the aqueous outflow pathway, assuming that the entire pressure drop in the outflow pathway occurs across the inner wall endothelium. Note that if this structure is not responsible for the bulk of aqueous

TABLE 193–4. **Hydraulic Conductivity (L_p) of Endothelia**

Type	Endothelium	L_p (cm²/sec/g) × 10^{11}	Reference
Not fenestrated	Brain capillary	0.03	Renkin[202]
	Cornea	1.6	Hedbys and Mishima[201]
	Lung capillary	3.4	Renkin[202]
	Skeletal muscle capillary	2.5–7	Renkin[202]
	Aorta	9	Vargas et al[203]
	Mesentery, omentum	50	Renkin[202]
Fenestrated	Intestinal mucosa	32–130	Levick and Smaje[98]
	Synovium (knee)	120	Levick and Smaje[98]
	Renal glomerulus	400–3100	Renkin[20] Levick and Smaje[98]
Not fenestrated	Aqueous outflow pathway	4000–9000*	Ten Hulzen and Johnson[26]

*Flow rate of 2 μL/min driven by a pressure drop of 5 mm Hg through a cross-sectional area of between 0.054 and 0.13 cm² (canal width of 150 to 350 μm; canal length around the eye of 3.6 cm[26]); note that this is not necessarily the L_p for the inner wall endothelium because this calculation is based on the entire pressure drop through the outflow pathway—L_p for the inner wall endothelium is likely *higher* than this value.

outflow resistance, it would have an even higher hydraulic conductivity than that computed here!

The hydraulic conductivity of the aqueous outflow pathway is higher than that of any other endothelium; in addition, the other endothelia of relatively high hydraulic conductivity (e.g., glomerulus) are fenestrated endothelia, whereas the endothelium of Schlemm's canal is a continuous endothelium with tight junctions. Compared with other endothelia that have tight junctions, the hydraulic conductivity of the endothelium of Schlemm's canal is even more exceptional.

From this, we can conclude that fluid likely passes through this endothelium by a different mechanism than that used to pass through other endothelia. In other endothelia, fluid passes either between the cells, through the cell's junctional complexes[97] or, for fenestrated endothelia, through the fenestra.[98] Raviola and Raviola[99] characterized the intercellular pathway between endothelial cells in the inner wall endothelium and showed that only an insignificant fluid flow could pass via this route. What appears to be novel about the inner wall endothelium of Schlemm's canal is the existence of large pores through which fluid can flow. Most of these pores pass intracellularly, but a significant fraction are intercellular (Fig. 193–48)[81] and may correspond to a paracellular pathway described by Epstein and Rohen.[79] Confirmation that fluid passes through these large pores comes from filtration studies showing that micron-sized particles can pass through the outflow pathway.[32, 35, 100, 101]

The flow resistance of the pores of the inner wall endothelium was determined theoretically by Bill and Svedbergh.[44] In a painstaking scanning electron microscopic study, they characterized the pore size distribution of the inner wall endothelium and then used Sampson's law to compute the flow resistance of this structure. Sampson's law is similar to the famous law of Poiseuille, but although the latter characterizes the flow resistance of long circular pores, the former characterizes the flow resistance of short, widely spaced circular openings in an otherwise impenetrable sheet. Specifically, Sampson[102] found that the flow resistance (R: ratio of pressure drop, ΔP, to flowrate, F) of a single such opening is:

$$R = \frac{\Delta P}{F} = \frac{24\ \mu m}{D^3} \qquad \text{(Eq. 6)}$$

where D is the pore diameter and μ is the fluid viscosity. Using this relationship, Bill and Svedbergh found that the pores of the inner wall endothelium could account for only approximately 10% of aqueous outflow resistance. Other investigators[103–105] have confirmed this result.

It should be recalled here that an increase in IOP leads to an increase in the number of inner wall pores.[46, 106] The observation that an increase in IOP does not result in a facility increase[60] provides further evidence that the inner wall endothelium accounts for only a small part of the outflow resistance.

Although this result appears to rule out the inner wall endothelium as a major site of aqueous outflow resistance, several experimental findings by Hamanaka and Bill[107, 108] appear to be in conflict with this finding. They perfused live primate eyes and found that after the use of a chelating agent (ethylenediaminetetraacetic acid[107, 211]) or a proteolytic enzyme (α-chymotrypsin[108]), ruptures of the inner wall were produced that reduced outflow resistance by much more than could be accounted for by the apparent resistance of the inner wall endothelium (based on the calculated resistance of the inner wall pores). Furthermore, removal of these agents led to a reversal of the ruptures and a return toward baseline of the outflow resistance.

Johnson and associates[80] pointed out that a hydrodynamic interaction (the funneling effect) between the inner wall pores and the JCT, which lies immediately below these pores, could explain the findings of Hamanaka and Bill. In this situation, the pores themselves contribute negligible flow resistance, but because they force the fluid to "funnel" through those regions of the JCT nearest the pores, their number and size can greatly increase the effective outflow resistance of the JCT. However, two studies[41, 81] failed to find a correlation between outflow facility and inner wall pore density as would be expected if the funneling effect contributed to aqueous outflow resistance.

As regards the glaucomatous eye, there is one report[109] indicating that inner wall pore density is greatly decreased in these eyes when compared with normal eyes. However, this report also identified a correlation between inner wall pore density and outflow facility that was later suggested to be due to the fixation conditions.[41] It is not currently known whether POAG is associated with an increased outflow resistance of the inner wall endothelium.

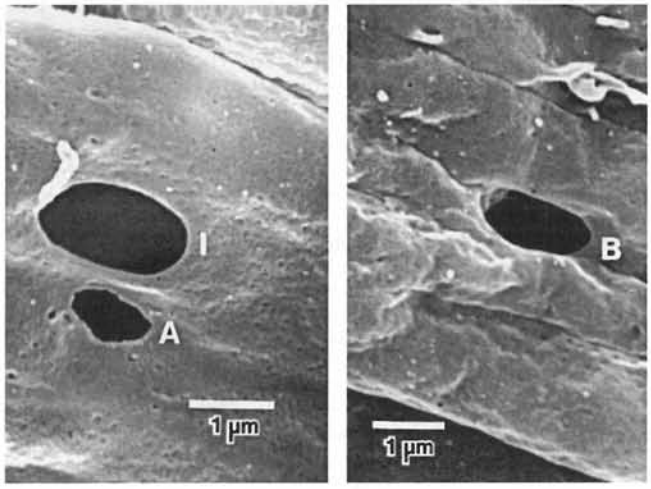

FIGURE 193–48. Scanning electron micrographs of pores in inner wall endothelium. *Left,* Intracellular pore (I) and artifactual pore (A); *right,* intercellular or border pore (B). (From Ethier CR, Coloma FM, Sit AJ, Johnson M: Two pore populations in the inner wall endothelium of Schlemm's canal. Invest Ophthalmol Vis Sci 39:2041, 1998.)

The Outflow Resistance of the Juxtacanalicular Connective Tissue and the Role of the Extracellular Matrix

When the other structures in the aqueous outflow pathway had been ruled out as being capable of generating a significant fraction of aqueous outflow resistance, it was natural to conclude that the JCT, with its small openings and tortuous flow pathways, was the principal site of outflow resistance. However, the first theoretical calculations[110, 111] of the flow resistance of this region indicated that these flow passages,

as viewed using conventional electron microscopic histologic techniques, would generate an insignificant fraction of outflow resistance.

These studies employed porous media theory to characterize the flow resistance of the JCT, as had been done in other connective tissues.[96] The specific hydraulic conductivity (K) of a tissue is related to the flow resistance of a tissue *(R)* through Darcy's law as:

$$R = \frac{\Delta P}{F} = \frac{\mu L}{KA} \qquad \text{(Eq. 7)}$$

or in terms of the hydraulic conductivity defined in Equation 5:

$$K = L_p \mu L \qquad \text{(Eq. 8)}$$

Here, μ is the fluid viscosity and L is the length of the porous medium in the direction of flow.

The K value that characterizes the flow resistance of a tissue can be determined experimentally, but it also can be determined from photomicrographs. Carmen-Kozeny theory relates the structure of a low-porosity porous medium to K as:

$$K = \frac{\epsilon D_h^2}{64} \qquad \text{(Eq. 9)}$$

where D_h is the hydraulic diameter of the open spaces available for flow and ϵ is the porosity of the medium. A list of specific hydraulic conductivities for different connective tissues is found in Table 193–5.

Using Carmen-Kozeny theory combined with conventional transmission electron microscopy,[110, 112] it was found that the porosity of the JCT was approximately 15 to 25%, D_h was approximately 1 to 1.5 μm, and most importantly, K of the JCT was calculated to be approximately 2000 to 10,000 $\times 10^{-14}$ cm² based on the photomicrographs. Comparing with Table 193–2, we find that *K* would need to be in the range of 3 to 65 $\times 10^{-14}$ cm² for the JCT to generate the bulk of aqueous outflow resistance. Since the value of *K* determined morphometrically from photomicrographs was two orders of magnitude or more larger than this, Ethier and associates[110] concluded that the JCT, as visualized using conventional transmission electron microscopy, could not generate a significant outflow resistance. Other investigators have confirmed this conclusion.[26, 112] It thus followed that either this region was filled with an extracellular matrix gel that was poorly visualized using conventional transmission electron microscopy techniques or that this region was not the primary site of outflow resistance.

We can use Equation 9 to understand these possibilities. Either the hydraulic diameter in the JCT is much smaller than 1 μm (the value of D_h found to characterize the JCT from the photomicrographs) or the effective porosity is much lower than that seen in the JCT. In the latter case, the porosity would have to be on the order of 0.001 to 0.01. This approaches the low porosity of the inner wall endothelium (it has few pores relative to its surface area),[80] and this is the reason that the inner wall endothelium is an attractive site for generating outflow resistance. In the former case, D_h would have to be on the order of 50 nm or so to generate the required flow resistance. This is of the same order of magnitude as the spacing between fibrils on an extracellular matrix gel[113] and motivates a consideration of the flow resistance of the extracellular matrix in the JCT.

The extracellular matrix is composed of collagen, elastin, glycoproteins, and the proteoglycans. The proteoglycans, which consist of a protein core to which glycosaminoglycans are attached, are poorly visualized using conventional histochemical techniques.[114] The glycosaminoglycans are highly negatively charged structures that are space filling as a consequence of this charge. As the glycosaminoglycans are known to generate flow resistance in other connective tissues,[96] it is natural to assume that they might be responsible for generating the bulk of aqueous outflow resistance.

Although the outflow pathways of nonprimate eyes seem to be sensitive to glycosaminoglycan-degrading agents,[58, 86, 115–121] the evidence is less clear for the primate eye. Pedler[117] and Grant[24] found no significant effect of testicular hyaluronidase on human outflow resistance. However, Peterson and Jocson[86] found a significant effect of testicular hyaluronidase on enucleated primate eyes, and Sawaguchi and associates[122] reported that chondroitinase ABC decreased IOP in living monkeys as compared with control eyes receiving heat-inactivated enzymes. In contrast, Hubbard and associates[123] found no effect of chondroitinase ABC or *Streptomyces* hyaluronidase on IOP or outflow facility, either chronically or acutely, in living monkeys.

Whether or not outflow resistance is generated by the extracellular matrix of the primate JCT, there is strong evidence that the JCT generates a significant outflow resistance in this species. Using the same technique described earlier for Schlemm's canal, Mäepea and Bill measured the pressure at different locations in the JCT.[88] After measuring the pressure in the canal with the micropipette tip, they pushed the tip through the inner wall endothelium and found little increase in pressure. This suggested that there was not a major pressure drop across the inner wall endothelium. Pushing the micropipette tip a few microns further, they found a significant pressure rise increasing to nearly the IOP level. These results indicated that at low IOP (9 mm Hg—the spontaneous pressure level measured in these mon-

TABLE 193–5. **Specific Hydraulic Conductivity (K) of Connective Tissues**

Tissue	K (cm²) × 10¹⁴	Reference
Anterior lens capsule	0.1	Fels[204]
Descemet's membrane	0.1–0.2	Fatt[205]
Bruch's membrane	0.5–1.5	Starita et al[206]
Glomerular basement membrane	2	Robinson and Walton[207]
Aortic wall	0.5–2.5	Levick[96]
Corneal stroma	0.5–1.2	Levick[96]
Sclera	1.4	Levick[96]
Synovium	1.5–7	Levick[208]
Cartilage	1–10	Mow et al[209]
Vitreous humor	1500–6800	Fatt[210]
Aqueous outflow pathway	3–6.5	i*
Aqueous outflow pathway	30–65	j*

*Flow rate of 2 μL/min driven by a pressure drop of 5 mm Hg through a cross-sectional area between 0.054 and 0.13 cm² (canal width of 150 to 350 μm; canal length around the eye of 3.6 cm[26]); thickness of flow-resistive region (JCT) of 1 μm (i) or 10 μm (j).

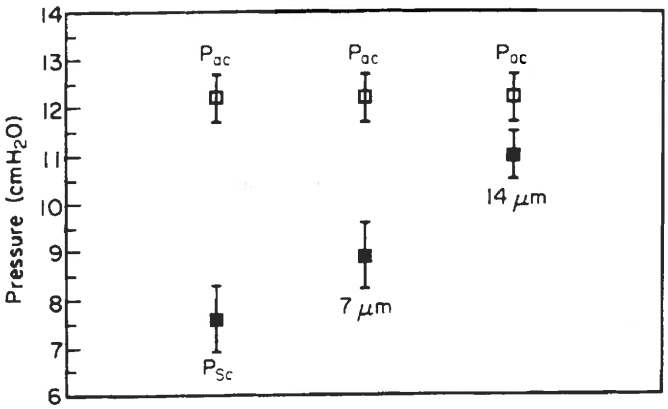

FIGURE 193–49. Micropressure measurements in a monkey at its spontaneous IOP (P_{ac}) in Schlemm's canal (P_{sc}) and at 7 and 14 μm from the inner wall endothelium in the JCT. Mean ± S.E.M. n = 5. (From Mäepea O, Bill A: Pressures in the juxtacanalicular tissue and Schlemm's canal in monkeys. Exp Eye Res 6:879–883, 1992.)

keys), most of the outflow resistance in these eyes (under general anesthesia) was located in the JCT, approximately 7 to 14 μm from the inner wall endothelium (Fig. 193–49). At higher, more physiologic pressure (15 mm Hg), the tissue causing most of the flow resistance was found to have moved closer to the inner wall (Fig. 193–50).

Unconventional Outflow Facility Resistance

As mentioned earlier, the uveoscleral or uveovortex flow is a second pathway by which aqueous humor can pass out of the eye. We examine here how this flow is measured and review the evidence for where and how outflow resistance is generated.

MEASUREMENT OF UNCONVENTIONAL OUTFLOW

Measurement of the fractional distribution of how the aqueous humor outflow leaves the eye is a difficult experimental

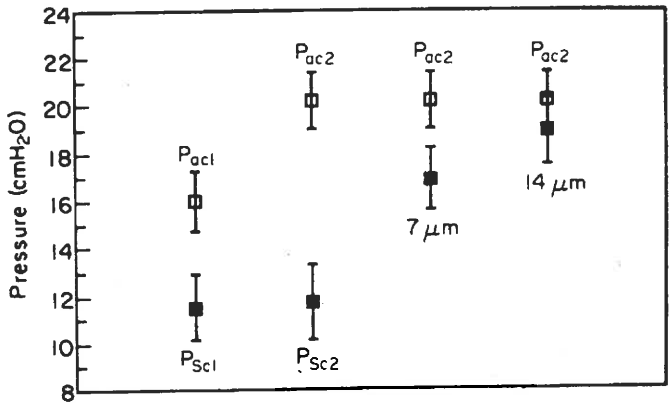

FIGURE 193–50. Micropressure measurements in a monkey at its spontaneous IOP (P_{ac1}) and an increased pressure (P_{ac2}) in Schlemm's canal (P_{sc}) and at 7 and 14 μm from the inner wall endothelium in the JCT. Mean ± S.E.M. n = 5. (From Mäepea O, Bill A: Pressures in the juxtacanalicular tissue and Schlemm's canal in monkeys. Exp Eye Res 6:879–883, 1992.)

technique, not only technically but also conceptually. How does one go about determining where one fraction of the aqueous goes while being sure that transport through the other pathways does not affect this measurement? Three techniques have been described for measuring the unconventional outflow: (1) using tracers to see where and to what extent the tracers accumulate in the unconventional outflow pathway,[19, 55] (2) using tracers and determining their concentration in the general circulation after a perfusion through the outflow pathway,[22] and (3) measurements of total outflow resistance, aqueous inflow rate, IOP, and episcleral venous pressure that are then used to calculate the unconventional outflow rate based on several assumptions.[64]

Macromolecules, such as radioactive albumin, have relatively low diffusion coefficients and thus are useful as tracers because they are normally transported by bulk flow. The high molecular weight tends to inhibit them from passing through dense connective tissues or blood vessel walls. It is then useful to assume that when perfused through the aqueous outflow pathway, such tracers will pass through the conventional outflow pathway into the general circulation (since they do not pass any such barriers). However, if these tracers are carried by the flow through the unconventional outflow pathway, they will remain in the ocular tissues, trapped either by the dense connective tissues or blood vessel walls that the fluid must ultimately pass.

By perfusing with a solution containing such a tracer, one can then stop the perfusion after different time points (e.g., 30 minutes to several hours) and section the eye to determine the concentration of tracer that has accumulated in tissues. The unconventional flow rate can then be calculated by dividing the amount of tracer recovered in the tissues per unit time by the mean concentration of tracer in the anterior chamber. This technique is perhaps the most direct measure of unconventional outflow, but it assumes that the tracers pass through the tissue in the same fashion as does the fluid (probably a reasonable assumption except perhaps in the sclera, as discussed later). Furthermore, the assumption is made that tracer that diffuses out of the conventional pathway does not enter the ocular tissues (a questionable assumption in the anterior uvea and especially the anterior sclera).

The second technique is similar but involves the use of a smaller tracer such as fluorescein and does not require tissue dissection. This tracer should not only move with the aqueous humor but should also be able to pass through connective tissues and, in particular, through vessel walls to enter the circulation. If the aqueous humor passes through a uveovortex pathway, one would expect the concentration of fluorescein in the vortex veins to be higher than that of the general circulation. By measuring this difference, one can determine the rate of flow of aqueous humor into these vessels. The limitations of this technique include that only the fraction of the unconventional outflow that passes into the vortex veins is measured, and it is assumed that none of the tracer traveling with the fluid along this pathway is lost. A related method determines the conventional outflow rate by perfusing radiolabeled albumin and determining the amount accumulating in the general circulation. A calculation of conventional outflow can then be made, assuming that albumin exits the eye only through the conventional route. The unconventional outflow can be calculated as the

difference between the inflow and the conventional outflow rate. The results of this calculation are similar to those based on the amount of tracer material entering the ocular tissues.

Finally, there are methods that deduce unconventional outflow based on other outflow parameters that are more easily measured. In general, aqueous inflow is measured and conventional outflow is estimated. The difference between these two quantities is unconventional outflow. These techniques are imprecise and are to some extent dependent on assumptions that may not be valid. For instance, the assumptions that unconventional outflow is not pressure-dependent whereas conventional outflow increases linearly with pressure, have some error involved with them. Furthermore, since this method involves subtraction of two quantities of approximately equal order of magnitude (inflow and conventional outflow) to determine a quantity of a smaller order of magnitude (unconventional outflow), small errors in the former two quantities can lead to large errors in the latter. However, the major advantage of these techniques is that they can be used noninvasively, and thus they are of considerable importance for human studies.

EVIDENCE AS TO THE ROUTE OF UNCONVENTIONAL DRAINAGE OF AQUEOUS HUMOR AND ITS CHARACTER

The two fundamental questions regarding unconventional outflow in the normal eye are, What is the pathway for this flow and how is this flow affected by changes in IOP? The pioneering studies of Bill[19] demonstrated that the unconventional outflow is pressure-insensitive. He found that in live primates, at an IOP of 11 mm Hg, the unconventional outflow was 0.44 μL/min, whereas at an IOP of 22 mm Hg, this outflow increased only to 0.63 μL/min; in contrast, conventional outflow increased from 0.8 to 4.18 μL/min.

Bill[17] provided a possible mechanism for this pressure-insensitivity of unconventional outflow. In the suprachoroidal space, the pressure is lower than that in the anterior chamber by a few millimeters of mercury.[124] Bill postulated that the suprachoroidal space was compressed by the difference between IOP and the pressure in the suprachoroidal space. Thus increasing IOP will further compress the suprachoroidal space, increasing flow resistance and inhibiting any further increase in flow.

However, other investigators[22, 63, 125] have found flow through this pathway to be more pressure-sensitive than Bill did. Pederson and associates[22] pointed out that if the unconventional outflow pathway is a uveovortex rather than uveoscleral pathway, one would expect unconventional outflow to be less pressure-sensitive than conventional aqueous outflow. In this case, the driving force for uveal adsorption of the aqueous humor would depend on the Starling forces, and thus readsorption would depend on the colloid osmotic pressure of the blood; IOP would play only a minor role in the readsorption. This leads us to the question of the route by which unconventional outflow exits the eye.

This pathway is best demonstrated using tracers. The pioneering studies by Bill,[13, 14] demonstrating that flow along this pathway leads to accumulation of tracer in the anterior sclera, the posterior sclera, and finally the orbital tissues, provided strong evidence of a *uveoscleral* outflow pathway. However, it is possible that although the tracer passes along a uveoscleral pathway, the fluid carrying the tracer passes through a *uveovortex* pathway while leaving the tracer in the sclera to diffuse across into the orbit.

Calculations of the diffusional transport properties of albumin support this possibility. The diffusion flux of a tracer across a tissue is:

$$D_0 (1 - \Phi) A \frac{\Delta C}{L} \qquad \text{(Eq. 10)}$$

whereas the convective flux of a tracer through a tissue is:

$$F_\mu (1 - \Phi) C \qquad \text{(Eq. 11)}$$

Here D_0 is the diffusion coefficient of the tracer in free solution (for albumin 6×10^{-7} cm²/sec); Φ is the extent to which the tracer is retarded, relative to the fluid flow, from moving by the extracellular matrix (0 is unhindered, 1 completely hindered); A is the cross-sectional area facing diffusion (11.5 cm² is the total scleral area[126]); and ΔC is the concentration difference across the sclera, which we assume is the same as the concentration of tracer in the suprachoroidal space, C. The thickness of the sclera is L (0.6 mm[126]), and F_u is the unconventional outflow rate.

We can calculate the ratio of these two quantities and find that for an unconventional outflow rate of 1 μL/min (as high as it is likely to be), the ratio of diffusional transport to convective transport (assuming that the flow is uveoscleral) is approximately 7! In other words, for these parameters, diffusional transport of the tracer across the sclera is nearly an order of magnitude higher than transport of the tracer by convection. Thus, there is no need for a flow to carry tracer across the sclera, as it can diffuse across on its own. This then indicates that just because tracer is found in the orbital tissue does not mean it arrived there by bulk flow, and therefore the appearance of tracer in the orbit is not proof of a uveoscleral flow.

Direct evidence for a uveovortex pathway was provided by Pederson and associates[22] who demonstrated that after perfusion of the anterior chamber with fluorescein, the concentration of fluorescein in the vortex veins was higher than that in the general circulation, in an amount consistent with a significant unconventional outflow.

Further evidence for a uveovortex pathway, and against a uveoscleral pathway, comes from consideration of the flow resistance of the sclera itself. The flow across the sclera is pressure-dependent,[125] and thus if the flow resistance for fluid crossing the sclera were the major site of unconventional outflow resistance, one would expect that unconventional outflow would be pressure-dependent, in contrast to the available evidence. Thus we must conclude that the dominant flow resistance in the unconventional outflow pathway is elsewhere. The available evidence suggests that the ciliary muscle is the dominant site of unconventional outflow resistance because both cyclodialysis[63, 127] and $PGF_{2\alpha}$[55, 57] greatly increase unconventional outflow, whereas pilocarpine decreases it[20] (see Pharmacology of Aqueous Humor Drainage).

However, this leads to an inconsistency. The specific hydraulic conductivity of the sclera has been measured and found to be approximately 1×10^{-14} cm² (see Table 193–5). Using Darcy's law (Eq. 7) and the parameters given earlier, we can compute that at an IOP of 15 mm Hg, this would

result in a uveoscleral flow of approximately 0.3 μL/min. However, this calculation is made assuming that the only flow resistance in the outflow pathway is that of the sclera. If the sclera generates only a small fraction of unconventional outflow resistance, the resistance in the remainder of the pathway must be much higher, and the resulting flow through such a system would be much less than 0.3 μL/min, at variance with the published values of unconventional outflow (0.2 to 0.5 μL/min).[19, 20]

More likely, the fluid is drawn *osmotically* into the vortex veins. As mentioned previously, this would also explain the relative insensitivity to pressure of the flow because most of the driving force would then be that of osmotic pressure of the blood (with its high protein content) that draws the fluid into these vessels. Note that even if this is true, this conclusion does not invalidate studies[55] looking to measure changes in unconventional outflow using tracer techniques because the tracer must still cross the sclera to leave the eye. Note also that this hypothesis—unconventional fluid outflow passing into the vortex veins while aqueous humor proteins have to leave the unconventional pathway by diffusion across the sclera—allows new explanations of uveal effusion in nanophthalmos and other diseases with relatively impermeable scleras,[128, 129] since normal protein transport across the sclera must occur physiologically.

Differences in Other Species

Aqueous humor drainage in other species differs morphologically from that in higher primates in several respects. Rabbits, cats, dogs, and cows do not have a well-defined Schlemm's canal. In rabbits and cows, the aqueous humor drains into an angular plexus;[32, 130] in cats and dogs, the aqueous humor passes into a large intrascleral venous plexus in the limbus region, which also collects blood from the anterior and the posterior uvea.[131] A second difference is that the JCT in the human eye is somewhat different from that in other species; in the human, the JCT is rather dense and filled with extracellular material, whereas in other species, the JCT region, in so far as it can be clearly demarcated from the rest of the trabecular meshwork, is a relatively open structure with little extracellular material.

There are two major physiologic differences between the outflow pathway of the human eye and that of other species. The first is the washout that occurs during perfusion of nonhuman eyes, which is not seen in the human eye. The second difference relates to glaucoma, which appears to be nearly unique to the human eye.

Perfusion experiments of nonhuman eyes demonstrate a phenomenon known as the washout effect: the progressive decrease of outflow resistance with increasing time or volume perfused.[72] This phenomenon occurs for both living[132] and enucleated eyes[133] and is probably due to the washout of some substance or substances from the outflow routes. Studies performed so far, however, have suggested that there is no loss of glycosaminoglycans from the outflow pathway during a perfusion.[134] Perfusion of enucleated bovine eyes[134] and live primates[135] has shown that use of serum protein in the perfusion medium greatly reduces this washout phenomenon. Enucleated human eyes exhibit a stable outflow resistance during perfusion;[61, 136] no evidence has yet been presented as to why the human eye does not wash out.

The second and perhaps the most important difference is the uniqueness of the human eye with respect to the development of POAG.[137] Whereas vulnerability of the optic nerve to elevated pressure has been demonstrated in the primate eye,[138] ocular hypertension occurring as a chronic result of outflow obstruction is unique to the human eye.[138] Although a single family of beagles has been shown to demonstrate the characteristics of POAG, this disease in these beagles appears different in its early onset and its association with narrowing of the angle.[139] There has also been a report of a colony of primates in Puerto Rico demonstrating ocular hypertension and optic nerve damage; however, no evidence has yet been provided of outflow obstruction with open angles.[140]

It would be most interesting to determine if these two rather unique characteristics of the human eye—the lack of washout and vulnerability to ocular hypertension—are in some fashion related. It is especially the latter characteristic that makes glaucoma a difficult disease to study in its early stages because there is not yet an animal model.

Pharmacology of Aqueous Humor Drainage

A variety of agents are known to affect aqueous outflow (IOP) in primate and subprimate eyes (e.g., pilocarpine, epinephrine) by influencing outflow facility or by affecting unconventional outflow (e.g., $PGF_{2\alpha}$). It is beyond the scope of this chapter to provide an exhaustive review of all the literature. Instead, we review the basic knowledge of mechanisms of action (so far as they are known) and include preclinical studies that highlight the mechanism or mechanisms of action of current therapeutic agents used in the treatment of glaucoma.

MUSCARINIC AGENTS

Pilocarpine, a muscarinic agonist, has been used in the treatment of glaucoma for more than 100 years. However, its mechanism of IOP lowering has been elucidated relatively recently. Kaufman and Bárány[141] were the first to show that the ciliary muscle is essential in mediating muscarinic agonist-induced changes in outflow facility in the monkey eye in vivo. In their studies, they elegantly demonstrated that surgical disinsertion of the ciliary muscle from its proximal attachment to the scleral spur in monkey eyes prevented an acute response to pilocarpine in outflow facility. Muscarinic agonists are thought to bind to receptors in the ciliary muscle, causing contraction of the muscle and displacement of the scleral spur, thus opening Schlemm's canal and facilitating aqueous humor flow out of the eye.[95, 142]

Recent studies have demonstrated that cells derived from human trabecular meshwork[143] and human trabecular meshwork tissue in situ[144–146] also have muscarinic receptors and that these cells have contractile properties that have been demonstrated histologically[147] and physiologically.[148] Collectively, these studies have raised the possibility that stimulation of muscarinic receptors in cells located within the outflow pathways themselves may have a direct effect on outflow facility independent of the ciliary muscle. Indeed, Kaufman and Bárány[141] showed that there was a small residual effect on outflow facility by pilocarpine even after the ciliary muscle had been severed from the scleral spur. A

recent study showed that the human outflow apparatus can respond to muscarinic agonists with an increase in outflow facility without an intact ciliary muscle.[149]

ADRENERGIC AGENTS

Like pilocarpine, epinephrine has been used for a number of years in the treatment of glaucoma. Epinephrine has been shown to increase outflow facility in human[150–152] and primate[153, 154] eyes, but the mechanism by which it acts remains obscure and somewhat controversial. It has become clear, however, that the mechanism of action involves β-adrenergic receptors, since the β-blocker timolol antagonizes the facility-increasing action of epinephrine.[152]

Evidence from autoradiographic studies of human outflow tissue,[144] along with cell culture studies,[142, 143, 146] and physiologic studies in human eyes and monkey eyes,[147, 148, 153, 155–162] all point to the role of β-adrenergic receptors and subsequent accumulation of cyclic AMP in mediating epinephrine-induced increases in outflow facility that lead to a reduction in IOP. Some studies show that the effect of epinephrine can be blocked by indomethacin, which raises the possibility that the ultimate effect on facility may involve the generation of prostaglandins.[163–167] Further work is necessary to elucidate how the increase in cyclic AMP, and possible involvement of prostaglandins, leads to an increase of outflow facility.

PROSTAGLANDINS

Latanoprost (Xalatan), an analog of $PGF_{2\alpha}$, is currently used in the treatment of glaucoma. The large IOP reductions seen with the use of $PGF_{2\alpha}$, and the lack of an increase in outflow facility or a decrease in aqueous humor secretion rate,[168–171] suggested that these prostaglandins act through the unconventional outflow pathway. Confirmation of this hypothesis was provided by measurements of unconventional outflow (using a tracer accumulation technique) in primates after $PGF_{2\alpha}$ treatment.[55]

Crawford and Kaufman,[172] in a clever study, validated this conclusion by noting that since pilocarpine reduces unconventional outflow,[20] one would expect pilocarpine to antagonize the effect on unconventional outflow of $PGF_{2\alpha}$, a hypothesis they affirmed, as did Nilsson and colleagues[173] with latanoprost. The mechanism of action of latanoprost and $PGF_{2\alpha}$ may involve a widening of the spaces between ciliary muscle bundles, thus decreasing the resistance to flow through the unconventional pathway. Consistent with this is the observation that prostaglandins appear to disrupt the extracellular matrix between muscle bundles in the ciliary muscle, presumably increasing the unconventional outflow rate.[57] Pilocarpine may act in opposition to this effect of these prostaglandins by tensing the ciliary muscle and decreasing the spaces between the ciliary muscle bundles.

OTHER AGENTS

Agents That Affect the Cytoskeleton

Agents that alter cytoskeletal elements, such as the sulfhydryl-active ethacrynic acid, cause profound increases in outflow facility in monkey and human eyes.[174, 175] The morphologic correlates of this facility change are effects on the structure of JCT as well as disruption of the inner wall.[174, 176] Interestingly, ethacrynic acid caused marked disruption of actin and tubulin in the trabecular and endothelial cells.[176, 177] Cytochalasins B and D, which disrupt actin filaments in cells, also cause marked changes in outflow facility in primate eyes with similar morphologic changes.[178–181]

Calcium Channel Blockers

Calcium channel blockers represent a heterogeneous group of drugs that were initially developed for use in the management of patients with angina pectoris.[182] These drugs alter calcium uptake across cell membranes, affecting intracellular calcium uptake or release, or both. In blood vessels, these effects reduce vascular resistance and help prevent vasospasm.[183] The ocular effects of calcium channel blockers are of great interest for their potential clinical role, particularly for the management of retinal occlusive diseases, ischemic optic neuropathy, and glaucoma.

In experimental and clinical studies, systemic administration of calcium channel blockers has demonstrated variable effects, with a trend toward reduction of IOP.[184–190] Topical administration of verapamil in humans has generally shown a decrease in IOP.[187, 191–193] In rabbits, the mechanism of action of lowering IOP appears to result, at least in part, from increased outflow facility.[185] This is also the case in the perfused human anterior segment.[194]

The role played by calcium restriction in aqueous outflow physiology is poorly understood. Verapamil itself produces a modest but consistent increase in cyclic AMP in the perfused human eye.[194] Verapamil-induced reduction in IOP is partially inhibited by topically applied flurbiprofen in normotensive and glaucomatous monkey eyes,[195] suggesting that prostanoids may play a role in the ocular hypotensive effect of verapamil. Other possible effects of calcium channel blockers are unproved and include altered aqueous humor dynamics due to a hydrostatic effect on ciliary body perfusion and an osmotic component due to altered ciliary body secretion[196] or changes of episcleral venous pressure.

LASER TRABECULOPLASTY

Although laser trabeculoplasty is not a pharmacologic treatment, its wide use as an outpatient glaucoma procedure, and its frequent combination with other pharmacologic agents, makes it appropriate to consider in this setting. Since laser trabeculoplasty was first described,[89] it has been recognized that this procedure increases outflow facility by a mechanism other than the simple creation of holes in the trabecular meshwork through which fluid can flow. In fact, if such holes are created (using, e.g., a yttrium-aluminum-garnet laser), these holes quickly heal and close off.[89, 197]

Wise and Witter[89] hypothesized that laser trabeculoplasty worked in a mechanical fashion, either by direct collagen shrinkage or formation of scar tissue that then contracts, leading to tension on the remaining trabecular meshwork. This tension was presumed to open the intertrabecular spaces or prevent collapse of Schlemm's canal.[90] Support for this hypothesis can be found in the work by Melamed and Epstein[198] showing that the regions of the trabecular mesh-

work undergoing laser treatment were nonfiltering with a diversion of flow to the remaining meshwork.

However, studies by Van Buskirk and associates[90] demonstrated that in enucleated human eyes, laser-induced shrinkage of the trabecular tissues did not lead to an acute increase in outflow facility. This is consistent with the clinical observation that it takes approximately 3 to 6 weeks for outflow facility to improve after laser treatment.[89] Although it could be that scarring caused by the laser takes several weeks for its full action to be manifested in the outflow pathway, another possible mechanism of action is that of a biologic response:[90, 199, 200] the injury caused by the laser burn may provide a stimulus for a biologic response that leads to an improvement in outflow facility. Possible mechanisms might include increased phagocytotic activity and activation of cells leading to altered metabolic activity or increased levels of cell division. Evidence for the latter has been provided.[200] However, no conclusive experiment has yet been performed to distinguish whether the action of laser trabeculoplasty is primarily mechanical or biologic and to delineate the detailed mechanism by which this improvement in outflow facility occurs.

REFERENCES

1. Leber T: Studien ber den Flssigkeitswechsel im Auge. Graefes Arch Clin Exp Ophthalmol 19:87, 1873.
2. Schwalbe G: Untersuchen ber die Lymphbahnen des Auges und ihre Begrenzungen. Arch Mikrosk Anat 6:261, 1870.
3. Knies M: Die resorption von blut in der vorderen augenkammer. Arch Pathol Anat Physiol Klin Med 62:537, 1875.
4. Smith P: On the escape of fluid from the aqueous and vitreous chambers under different pressure. Ophthalmol Rev 7:193, 1888.
5. Thomassen TL: On aqueous veins. Acta Ophthalmol 25:369, 1947.
6. Seidel E: Weitere experimentelle Untersuchungen ber die Quelle und den Verlauf der intraokularen Saftstrmung. XVIII. Mikroskopische Beobachtungen ber den Mechanisms des Abfluss aud der Vorderdammer des debenden Tieres bei physiologischem Augendrucke. Graefes Arch Clin Exp Ophthalmol 111:167, 1923.
7. Ascher KW: Aqueous veins. Am J Ophthalmol 25:31, 1942.
8. Goldmann H: Weitere Mitteilungber den Abfluss des Kammerwassers beim Menschen. Ophthalmologica 112:344, 1946.
9. Tripathi RC: Comparative physiology and anatomy of the aqueous outflow pathway. *In* Davson H, Graham LT (eds): The Eye. Comparative Physiology. New York, Academic, 1974.
10. Ashton N: Anatomical study of Schlemm's canal and aqueous veins by means of neoprene casts: Part I. Br J Ophthalmol 35:291, 1951.
11. Ujiie K, Bill A: The drainage routes for aqueous humor as revealed by scanning electron microscopy of corrosion casts. Scan Electron Microsc 2:829, 1984.
12. Henderson T: Principles of Ophthalmology. London, Heinemann, 1950.
13. Bill A: The albumin exchange in the rabbit. Acta Physiol Scand 60:18, 1964.
14. Bill A: The drainage of albumin from the uvea. Exp Eye Res 3:179, 1964.
15. Bill A, Hellsing K: Production and drainage of aqueous humor in the cynomolgus monkey (*Macaca irus*). Invest Ophthalmol 4:920, 1965.
16. Bill A: The aqueous humor drainage mechanism in the cynomolgus monkey (*Macaca irus*) with evidence for unconventional routes. Invest Ophthalmol 4:911, 1965.
17. Bill A: Basic physiology of the drainage of aqueous humor. *In* Bito LZ, Davson H, Fenstermacher JD (eds): The Ocular and Cerebrospinal Fluids. London, Academic Press, 1977.
18. Fatt I: Flow and diffusion in the vitreous body of the eye. Bull Math Biol 37:85, 1975.
19. Bill A: Conventional and uveo-scleral drainage of aqueous humour in the cynomolgus monkey (*Macaca irus*) at normal and high intraocular pressures. Exp Eye Res 5:45, 1966.
20. Bill A, Phillips CI: Uveoscleral drainage of aqueous humor in human eyes. Exp Eye Res 12:275, 1971.
21. Bill A: Blood circulation and fluid dynamics in the eye. Physiol Rev 55:383, 1975.
22. Pederson JE, Gaasterland DE, MacLellan HM: Uveoscleral aqueous outflow in the rhesus monkey: Importance of uveal reabsorption. Invest Ophthalmol Vis Sci 16:1008, 1977.
23. Sherman SH, Green K, Laties AM: The fate of anterior chamber fluorescein in the monkey eye. I: The anterior chamber outflow pathways. Exp Eye Res 27:159, 1978.
24. Grant WM: Experimental aqueous perfusion in enucleated human eyes. Arch Ophthalmol 69:783, 1963.
25. Holmberg A: The fine structure of the inner wall of Schlemm's canal. Arch Ophthalmol 62:956, 1959.
26. Ten Hulzen RD, Johnson DH: Effect of fixation pressure on juxtacanalicular tissue and Schlemm's canal. Invest Ophthalmol Vis Sci 37:114, 1996.
27. Gong H, Tripathi RC, Tripathi BJ: Morphology of the aqueous outflow pathway. Microsc Res Tech 33:336, 1996.
28. Lütjen-Drecoll E, Futa R, Rohen JW: Ultrahistochemical studies on tangential sections of trabecular meshwork in normal and glaucomatous eyes. Invest Ophthalmol Vis Sci 21:563, 1981.
29. Rohen JW, Futa R, Lütjen-Drecoll E: The fine structure of the cribriform meshwork in normal and glaucomatous eye as seen in tangential sections. Invest Ophthalmol Vis Sci 21:574, 1981.
30. Rohen JW, Lütjen-Drecoll E, Bárány E: The relationship between the ciliary muscle and the trabecular meshwork and its importance for the effect of miotics on aqueous outflow resistance. Graefes Arch Clin Exp Ophthalmol 172:23, 1967.
31. Rohen JW, van der Zypen E: The phagocytic activity of the trabecular meshwork endothelium. Graefes Arch Clin Exp Ophthalmol 175:143, 1968.
32. Johnson M, Johnson DH, Kamm RD, et al: The filtration characteristics of the aqueous outflow system. Exp Eye Res 50:407, 1990.
33. Inomata H, Bill A, Smelser GK: Aqueous humor pathways through the trabecular meshwork and into Schlemm's canal in cynomologus monkey *(Maccaca Irus)*. Am J Ophthalmol 73:760, 1972.
34. Bill A, Mäepea O: Mechanisms and routes of aqueous humor drainage. *In* Albert DM, Jakobiec FA (eds): Principles and Practice of Ophthalmology, vol 1: Basic Sciences. Philadelphia, WB Saunders, 1994.
35. Seidel E: Weitere experimentelle Untersuchungen ber die Quelle und den Verlauf der intraokularen Saftstrmung. IX Mitteilung. ber den Abfluss des Kammerwassers aus der vorderen AugenKammer. Graefes Arch Clin Exp Ophthalmol 104:357, 1921.
36. Garron LK, Fenney ML, Hogan MJ, McEwen WK: Electron microscopic studies of the human eye. Am J Ophthalmol 46:27, 1958.
37. Speakman JS: Aqueous outflow channels in the trabecular meshwork in man. Br J Ophthalmol 43:129, 1959.
38. Tripathi RC: Mechanism of the aqueous outflow across the trabecular wall of Schlemm's canal. Exp Eye Res 11:116, 1971.
39. Grierson I, Lee WR: Pressure-induced changes in the ultrastructure of the endothelium lining Schlemm's canal. Am J Ophthalmol 80:863, 1975.
40. Svedbergh B: Effects of intraocular pressure on the pores of the inner wall of Schlemm's canal. *In* Yamada E, Mishima S (eds): The Structure of the Eye. III. Jpn J Ophthalmol, Tokyo, Japan, 1976.
41. Sit AJ, Coloma FM, Ethier CR, Johnson M: Factors affecting the pores of the inner wall endothelium of Schlemm's canal. Invest Ophthalmol Vis Sci 38:1517–1525, 1997.
42. Kays J: Pore structure of the inner wall of Schlemm's canal. Invest Ophthalmol Vis Sci 6:381, 1967.
43. Bill A: Scanning electron microscopic studies of the canal of Schlemm. Exp Eye Res 10:214, 1970.
44. Bill A, Svedbergh B: Scanning electron microscopic studies of the trabecular meshwork and the canal of Schlemm: An attempt to localize the main resistance to outflow of aqueous humor in man. Acta Ophthalmol 50:295, 1972.
45. Segawa K: Pore structures of the endothelial cells of the aqueous outflow pathway: Scanning electron microscopy. Jpn J Ophthalmol 17:133, 1973.
46. Lee WR, Grierson L: Pressure effects on the endothelium of the trabecular wall of Schlemm's canal: A study by scanning electron microscopy. Graefes Arch Clin Exp Ophthalmol 196:255, 1975.
47. Lütjen-Drecoll E, Rohen JW: Uber die endotheliale auskleidung des Schlemm'schen kanals in silberimpragnationsbild. Graefes Arch Clin Exp Ophthalmol 180:249, 1970.

48. Johnstone MA, Grant WM: Pressure dependent changes in the structures of the aqueous outflow system of human and monkey eyes. Am J Ophthalmol 75:365, 1973.
49. Hoffman F, Dumitrescu L: Schlemm's canal under the scanning electron microscope. Ophthalmic Res 2:37, 1971.
50. Johnson M, Kamm RD: The role of Schlemm's canal in aqueous outflow from the human eye. Invest Ophthalmol Vis Sci 24:320, 1983.
51. Dvorak-Theobald G: Schlemm's canal: Its anastomoses and anatomic relations. Trans Am Ophthalmol Soc 32:574, 1934.
52. Rohen JW, Rentsch TJ: Uber ben bau des Schlemm'schen Kanals und seiner abflussweg beim menschen. Graefes Arch Clin Exp Ophthalmol 176:309, 1968.
53. Batmanov YE: Structure of the eye drainage system in man. Vestn Oftalmol 4:27, 1968.
54. Inomata H, Bill A, Smelser GK: Unconventional routes of aqueous humor outflow in cynomolgus monkey (*Macaca irus*). Am J Ophthalmol 73:893, 1972.
55. Gabelt BT, Kaufman PL: Prostaglandin $F_{2\alpha}$ increases uveoscleral outflow in the cynomolgus monkey. Exp Eye Res 49:389, 1989.
56. Bill A, Wlinder P-E: The effects of pilocarpine on the dynamics of aqueous humor in a primate (*Macaca irus*). Invest Ophthalmol 5:170, 1966.
57. Lütjen-Drecoll E, Tamm E: Morphological study of the anterior segment of cynomolgus monkey eyes following treatment with prostaglandin $F_{2\alpha}$. Exp Eye Res 47:761, 1988.
58. Bárány EH: In vitro studies of the resistance to flow through the angle of the anterior chamber. Acta Soc Med Ups 59:260, 1953.
59. Van Buskirk EM, Grant WM: Influence of temperature and the question of involvement of cellular metabolism in aqueous outflow. Am J Ophthalmol 77:565, 1974.
60. Brubaker RF: The effect of intraocular pressure on conventional outflow resistance in the enucleated human eye. Invest Ophthalmol Vis Sci 14:286, 1975.
61. Van Buskirk EM: Changes in the facility of aqueous outflow induced by lens depression and intraocular pressure in excised human eyes. Am J Ophthalmol 82:736, 1976.
62. Bill A: Effects of longstanding stepwise increments in eye pressure on the rate of aqueous humor formation in a primate (*Cercopithecus ethiops*). Exp Eye Res 12:184, 1971.
63. Toris CB, Pederson JE: Effect of intraocular pressure on uveoscleral outflow following cyclodialysis in the monkey eye. Invest Ophthalmol Vis Sci 26:1745, 1985.
64. Yablonski ME, Cook DJ, Gray J: A fluorophotometric study of the effect of argon laser trabeculoplasty on aqueous humor dynamics. Am J Ophthalmol 99:579, 1985.
65. Mäepea O, Bill A: The pressures in the episcleral veins, Schlemm's canal and the trabecular meshwork in monkeys: Effects of changes in intraocular pressure. Exp Eye Res 49:645, 1989.
66. Brubaker RF: Determination of episcleral venous pressure in the eye. A comparison of three methods. Arch Ophthalmol 77:110, 1967.
67. Grant WM: Clinical measurements of aqueous outflow. Arch Ophthalmol 46:113, 1951.
68. Bárány EH: Simultaneous measurement of changing intraocular pressure and outflow facility in the vervet monkey by constant pressure infusion. Invest Ophthalmol Vis Sci 3:135, 1964.
69. Epstein DL, Hashimoto JM, Grant WM: Serum obstruction of aqueous outflow in enucleated eyes. Am J Ophthalmol 86:101, 1978.
70. Epstein DL, Jedziniak JA, Grant WM: Obstruction of aqueous outflow by lens particles and by heavy-molecular-weight soluble lens proteins. Invest Ophthalmol Vis Sci 17:272, 1978.
71. Johnson M: The role of Schlemm's canal in aqueous outflow from the human eye. Masters thesis. Cambridge, MA, Massachusetts Institute of Technology, 1981.
72. Johnson M, Chen A, Epstein DL, Kamm RD: The pressure and volume dependence of the rate of wash-out in the bovine eye. Curr Eye Res 10:373, 1991.
73. Grant WM: Further studies on facility of flow through the trabecular meshwork. Arch Ophthalmol 60:523, 1958.
74. Moses RA: The effect of intraocular pressure on resistance to outflow. Surv Ophthalmol 22:88, 1977.
75. Hayashi M, Yablonski ME, Novack GD: Trabecular outflow facility determined by fluorophotometry in human subjects. Exp Eye Res 48:621, 1989.
76. Brubaker RF: Measurement of aqueous flow by fluorophotometry. *In* Ritch R, Shields MB (eds): The Glaucomas. St. Louis, CV Mosby, 1989.
77. Grant WM: Tonographic method for measuring the facility and rate of aqueous flow in human eyes. Arch Ophthalmol 44:204, 1950.
78. Kolker AE, Hetherington JJ: Tonometry and tonography (eds): Becker-Shaffer's Diagnosis and Therapy of the Glaucomas. St. Louis, CV Mosby, 1976.
79. Epstein DL, Rohen JW: Morphology of the trabecular meshwork and inner-wall endothelium after cationized ferritin perfusion in the monkey eye. Invest Ophthalmol Vis Sci 32:160, 1991.
80. Johnson M, Shapiro A, Ethier CR, Kamm RD: Modulation of outflow resistance by the pores of the inner wall endothelium. Invest Ophthalmol Vis Sci 33:1670, 1992.
81. Ethier CR, Coloma FM, Sit AJ, Johnson M: Two pore populations in the inner wall endothelium of Schlemm's canal. Invest Ophthalmol Vis Sci 39:2041, 1998.
82. McEwen WK: Application of Poiseuille's law to aqueous outflow. Arch Ophthalmol 60:290, 1958.
83. Rosenquist R, Epstein D, Melamed S, et al: Outflow resistance of enucleated human eyes at two different perfusion pressures and different extents of trabeculotomy. Curr Eye Res 8:1233, 1989.
84. Ellingsen BA, Grant WM: Trabeculotomy and sinosotomy in enucleated human eyes. Invest Ophthalmol 11:21, 1972.
85. Van Buskirk EM, Grant WM: Lens depression and aqueous outflow in enucleated primate eyes. Am J Ophthalmol 72:632, 1973.
86. Peterson WS, Jocson VL: Hyaluronidase effects on aqueous outflow resistance. Am J Ophthalmol 77:573, 1974.
87. Van Buskirk EM: Trabeculotomy in the immature, enucleated human eye. Invest Ophthalmol Sci 16:63, 1977.
88. Mäepea O, Bill A: Pressures in the juxtacanalicular tissue and Schlemm's canal in monkeys. Exp Eye Res 54:879, 1992.
89. Wise JB, Witter SL: Argon laser therapy for open-angle glaucoma. A pilot study. Arch Ophthalmol 97:319, 1979.
90. Van Buskirk EM, Pond V, Rosenquist RC, Scott TS: Argon laser trabeculoplasty. Studies of mechanism of action. Ophthalmology 91:1005, 1984.
91. Hamanaka T, Bill A: Platelet aggregation on the endothelium of Schlemm's canal. Exp Eye Res 59:249, 1994.
92. Nesterow AP: Role of blockade of Schlemm's canal in pathogenesis of primary open angle glaucoma. Am J Ophthalmol 70:691, 1970.
93. Moses RA: Circumferential flow in Schlemm's canal. Am J Ophthalmol 88:585, 1979.
94. Moses RA, Grodzki WJ Jr, Etheridge EL, Wilson CD: Schlemm's canal: The effect of intraocular pressure. Invest Ophthalmol Vis Sci 20:61, 1981.
95. Van Buskirk EM: Anatomic correlates of changing aqueous outflow facility in excised human eyes. Invest Ophthalmol Vis Sci 22:625, 1982.
96. Levick JR: Flow through interstitium and other fibrous matrices. Q J Exp Physiol 72:409, 1987.
97. Curry FE, Michel CC: A fiber matrix model of capillary permeability. Microvasc Res 20:96, 1980.
98. Levick JR, Smaje LH: An analysis of the permeability of a fenestra. Microvasc Res 33:233, 1987.
99. Raviola G, Raviola E: Paracellular route of aqueous outflow in the trabecular meshwork and canal of Schlemm. Invest Ophthalmol Vis Sci 21:52, 1981.
100. Huggert A: Pore size in the filtration angle of the eye. Acta Ophthalmol 33:271, 1955.
101. Huggert A, Holmberg A, Esklund A: Further studies concerning the filtration angle of the eye. Acta Ophthalmol 33:429, 1955.
102. Happel J, Brenner H: Low Reynolds Number Hydrodynamics. The Hague, the Netherlands, Martinus Nijhoff, 1983, pp 1–153.
103. Grierson I, Lee WR, Moseley H, Abraham S: The trabecular wall of Schlemm's canal: A study of the effects of pilocarpine by scanning electron microscopy. Br J Ophthalmol 63:9, 1979.
104. Erikkson A, Svedbergh B: Transcellular aqueous humor outflow: A theoretical and experimental study. Graefes Arch Clin Exp Ophthalmol 212:187, 1980.
105. Moseley H, Grierson I, Lee WR: Mathematical modelling of aqueous humor outflow from the eye through the pores in the lining of Schlemm's canal. Clin Phys Physiol Meas 4:47, 1983.
106. Grierson I, Lee WR: Pressure effects on flow channels in the lining endothelium of Schlemm's canal. Acta Ophthalmol 56:935, 1978.
107. Hamanaka T, Bill A: Morphological and functional effects of Na2EDTA on the outflow routes for aqueous humor in monkeys. Exp Eye Res 44:171, 1987.
108. Hamanaka T, Bill A: Effects of alpha-chymotrypsin on the outflow routes for aqueous humor. Exp Eye Res 46:323, 1988.

109. Allingham RR, deKater AW, Ethier CR, et al: The relationship between pore density and outflow facility in human eyes. Invest Ophthalmol Vis Sci 33:1661, 1992.
110. Ethier CR, Kamm RD, Palaszewski BA, et al: Calculations of flow resistance in the juxtacanalicular meshwork. Invest Ophthalmol Vis Sci 27:1741, 1986.
111. Seiler T, Wollensak J: The resistance of the trabecular meshwork to aqueous humor outflow. Graefes Arch Clin Exp Ophthalmol 223:88, 1985.
112. Murphy CG, Johnson M, Alvarado JA: Juxtacanalicular tissue in pigmentary and primary open angle glaucoma. The hydrodynamic role of pigment and other constituents. Arch Ophthalmol 110:1779, 1992.
113. Johnson M: Transport through the aqueous outflow system of the eye. Ph.D. thesis, Cambridge, MA, Massachusetts Institute of Technology, 1987.
114. Hascall VC, Hascall GK: Proteoglycans. *In* Hay ED (ed): Cell Biology of Extracellular Matrix. New York, Plenum, 1982.
115. Bárány EH, Scotchbrook S: Influence of testicular hyaluronidase on the resistance to flow through the angle of the anterior chamber. Acta Physiol Scand 30:240, 1954.
116. Bárány EH: The action of different kinds of hyaluronidase on the resistance to flow through the anterior chamber. Acta Ophthalmol 34:397, 1956.
117. Pedler C: The relationship of hyaluronidase to aqueous outflow resistance. Trans Ophthalmol Soc UK 76:51, 1956.
118. Melton CE, DeVille WB: Perfusion studies on eyes of four species. Am J Ophthalmol 50:302, 1960.
119. Van Buskirk MS, Brett J: The canine eye: In vitro dissolution of the barriers to aqueous outflow. Invest Ophthalmol Vis Sci 17:258, 1978.
120. Knepper PA, Farbman AI, Telser AG: Exogenous hyaluronidases and degradation of hyaluronic acid in the rabbit eye. Invest Ophthalmol Vis Sci 25:286, 1984.
121. Knepper PA: Glycosaminoglycans and aqueous outflow resistance. Ph.D. thesis. Ann Arbor, MI, Northwestern University, 1980.
122. Sawaguchi S, Yue BY, Yeh P, Tso MO: Effects of intracameral injection of chondroitinase ABC in vivo. Arch Ophthalmol 110:110, 1992.
123. Hubbard WC, Johnson M, Gong H, et al: Intraocular pressure and outflow facility are unchanged following acute and chronic intracameral chondroitinase ABC and hyaluronidase in monkeys. Exp Eye Res 65:177, 1997.
124. Emi K, Pederson JE, Toris CB: Hydrostatic pressure of the suprachoroidal space. Invest Ophthalmol Vis Sci 30:233, 1989.
125. Kleinstein RN, Fatt I: Pressure dependency of trans-scleral flow. Exp Eye Res 24:335, 1977.
126. Fatt I, Hedbys BO: Flow of water in the sclera. Exp Eye Res 10:243, 1970.
127. Bill A: The routes for bulk drainage of aqueous humor in rabbits with and without cyclodialysis. Doc Ophthalmol 20:157, 1966.
128. Ward RC, Gragoudas ES, Pon DM, Albert DM: Abnormal scleral findings in uveal effusion syndrome. Am J Ophthalmol 106:139, 1988.
129. Jin JC, Anderson D: Laser and unsutured sclerotomy in nanophthalmos. Am J Ophthalmol 109:575, 1990.
130. Tripathi BJ, Tripathi RC: Embryology of the anterior segment of the human eye. *In* Ritch R, Shields MB, Krupin T (eds): The Glaucomas. St. Louis, CV Mosby, 1989.
131. Bill A: Aspects of the drainage of aqueous humor in cats. Arch Ophthalmol 67:148, 1962.
132. Erickson KA, Kaufman PL: Comparative effects of three ocular perfusates on outflow facility in the cynomolgus monkey. Curr Eye Res 1:211, 1981.
133. Bárány EH, Woodin AM: Hyaluronic acid and hyaluronidase in the aqueous humor and the angle of the anterior chamber. Acta Physiol Scand 33:257, 1955.
134. Johnson M, Gong H, Freddo TF, et al: Serum proteins and aqueous outflow resistance in bovine eyes. Invest Ophthalmol Vis Sci 34:3549, 1993.
135. Kee C, Gabelt BT, Croft MA, et al: Serum effect on aqueous outflow during anterior chamber perfusion in monkeys. Invest Ophthalmol Vis Sci 37:1840, 1996.
136. Erickson-Lamy K, Schroeder AM, Bassett-Chu S, Epstein DL: Absence of time-dependent facility increase ("washout") in the perfused enucleated human eye. Invest Ophthalmol Vis Sci 31:2384, 1990.
137. Gelatt KN: Animal models for glaucoma. Invest Ophthalmol Vis Sci 16:592, 1977.
138. Gaasterland D, Kupfer C: Experimental glaucoma in the rhesus monkey. Invest Ophthalmol 13:455, 1974.
139. Peiffer RL, Gelatt KN: Aqueous humor outflow in beagles with inherited glaucoma: Gross and light microscopic observations of the iridocorneal angle. Am J Vet Res 41:861, 1980.
140. Dawson WW, Brooks DE, Hope GM, et al: Primary open angle glaucomas in the rhesus monkey. Br J Ophthalmol 77:302, 1993.
141. Kaufman PL, Bárány EH: Loss of acute pilocarpine effect on outflow facility following surgical disinsertion and retrodisplacement of the ciliary muscle from the scleral spur in the cynomolgus monkey. Invest Ophthalmol Vis Sci 15:793, 1976.
142. Grierson I, Lee WR, Abraham S: Effects of pilocarpine on the morphology of the human outflow apparatus. Br J Ophthalmol 62:302, 1978.
143. Woldemussie E, Feldman BJ, Chen J: Characterization of muscarinic receptors in cultured human iris sphincter and ciliary smooth muscle cells. Exp Eye Res 56:385, 1993.
144. Erickson K: Basic aspects of parasympathetic pharmacology. *In* Ritch R, Shields MB, Krupin T (eds): The Glaucomas. St. Louis, CV Mosby, 1995.
145. Abbas AK, Lichtman AH, Pober JS: Cellular and Molecular Immunology. Philadelphia, PA, WB Saunders, 1991.
146. Zhang X, Hernandez MR, Cheng MC, Erickson-Lamy K: Further characterization of muscarinic receptor subtype mRNA in the human ciliary muscle. Invest Ophthalmol Vis Sci 33:S1200, 1992.
147. deKater A, Shahsafaei A, Epstein D: Localization of smooth muscle and nonmuscle actin isoforms in the human aqueous outflow in the human aqueous outflow pathway. Invest Ophthalmol Vis Sci 33:424, 1992.
148. Wiederholt M, Lepple-Wienhues A, Stahl F: Contractile properties of trabecular meshwork and ciliary muscle. *In* Lütjen-Drecoll E, Rohen JW (eds): Basic Aspects of Glaucoma Research. III. Stuttgart, Schattauer, 1993.
149. Schroeder A, Erickson K: Low dose cholinergic agonists increase trabecular outflow facility in the human eye in vitro. Invest Ophthalmol Vis Sci 36:3330, 1995.
150. Becker B, Petitt TH, Gay AJ: Topical epinephrine therapy of open-angle glaucoma. Arch Ophthalmol 66:219, 1961.
151. Ballantine EJ, Garner L: Improvement of the coefficient of outflow in glaucomatous eyes. Arch Ophthalmol 66:314, 1961.
152. Thomas JV, Epstein DL: Timolol and epinephrine in primary open angle glaucoma. Transient additive effect. Arch Ophthalmol 99:91, 1981.
153. Bill A: Early effects of epinephrine on aqueous humor dynamics in vervet monkeys *(Cercopithecus ethiops)*. Exp Eye Res 8:35, 1969.
154. Bárány EH: Topical epinephrine effects on the true outflow resistance and pseudofacility in vervet monkeys studied by a new anterior chamber perfusion method. Invest Ophthalmol 7:88, 1968.
155. Bill A: Effects of norepinephrine, isoproterenol, and sympathetic stimulation on aqueous humor dynamics on vervet monkeys. Exp Eye Res 10:31, 1970.
156. Kaufman PL, Bárány EH: Adrenergic drug effects on aqueous outflow facility following ciliary muscle retrodisplacement in the cynomolgus monkey. Invest Ophthalmol Vis Sci 20:644, 1981.
157. Kaufman PL: Total iridectomy does not alter outflow facility responses to cyclic AMP in cynomolgus monkeys. Exp Eye Res 43:441, 1986.
158. Kaufman PL: Epinephrine, norepinephrine, and isoproterenol dose-outflow facility response relationships in cynomolgus monkey eyes with and without retrodisplaced ciliary muscle. Acta Ophthalmol 64:356, 1986.
159. Kaufman PL: Adenosine 3′,5′-cyclic-monophosphate and outflow facility in monkey eyes with intact and retrodisplaced ciliary muscle. Exp Eye Res 44:415, 1987.
160. Neufeld AH: Influences of cyclic nucleotides on outlow facility in the vervet monkey. Exp Eye Res 27:387, 1978.
161. Neufeld AH: The mechanisms of action of adrenergic drugs in the eye. *In* Drance SM, Neufeld AH (eds): Glaucoma: Applied Pharmacology in Medical Treatment. Orlando, FL, Grune & Stratton, 1984.
162. Neufeld AH, Sears ML: Adenosine 3′,5′-monophosphate analogue increases the outflow facility of the primate eye. Invest Ophthalmol 14:688, 1975.
163. Bhattacherjee P, Hammond BR: Effect of indomethacin on the ocular hypotensive action of adrenaline in the rabbit. Exp Eye Res 24:307, 1977.
164. Anderson L, Wilson WS: Inhibition by indomethacin of the increased facility of outflow induced by adrenaline. Exp Eye Res 50:119, 1980.
165. Camras CC, Feldman SG, Podos SM, et al: Inhibition of the epineph-

rine-induced reduction of intraocular pressure by systemic indomethacin in humans. Am J Ophthalmol 100:169, 1985.
166. Hubbard WC, Robinson JC, Kaufman PK: Inhibition of epinephrine's outflow facility increasing effect by indomethacin in the cynomolgus monkey. Invest Ophthalmol Vis Sci 32:868, 1991.
167. Hayasaka S, Sears M: Effects of epinephrine, indomethacin, acetylsalicylic acid, dexamethasone, and cyclic AMP on the in vitro activity of lysosomal hyaluronidase from the rabbit iris. Invest Ophthalmol Vis Sci 17:1109, 1978.
168. Crawford K, Kaufman PL, Gabelt BT: Effect of topical $PGF_{2\alpha}$ on aqueous humor dynamics in cynomolgus monkeys. Curr Eye Res 6:1035, 1987.
169. Camras CB, Podos SM, Rosenthal JS, et al: Multiple dosing of prostaglandin $F_{2\alpha}$ or epinephrine on cynomolgus monkey eyes. I: Aqueous humor dynamics. Invest Ophthalmol Vis Sci 28:463, 1987.
170. Camras CB, Bhuyan KC, Podos SM, et al: Multiple dosing of prostaglandin $F_{2\alpha}$ or epinephrine on cynomolgus monkey eyes. II: Slit-lamp biomicroscopy, aqueous humor analysis, and fluorescein angiography. Invest Ophthalmol Vis Sci 28:921, 1987.
171. Kerstetter JR, Brubaker RF, Wilson SE, Kullersrand LJ: Prostaglandin $F_{2\alpha}$-1-isopropyl ester lowers intraocular pressure without decreasing aqueous humor flow. Am J Ophthalmol 105:30, 1988.
172. Crawford K, Kaufman PL: Pilocarpine antagonizes prostaglandin $F_{2\,alpha}$–induced ocular hypotension in monkeys. Evidence for enhancement of uveoscleral outflow by prostaglandin $F_{2\,alpha}$. Arch Ophthalmol 105:1112, 1987.
173. Nilsson SFE, Samuelsson M, Bill A, Stjernschantz J: Increased uveoscleral outflow as a possible mechanism of ocular hypotension caused by prostaglandin $F_{2\alpha}$-1-isopropylester in the cynomolgus monkey. Exp Eye Res 48:707, 1989.
174. Epstein D, Freddo T, Bassett-Chu S, et al: Influence of ethacrynic acid on outflow facility in the monkey and calf eye. Invest Ophthalmol Vis Sci 28:2067, 1987.
175. Liang L, Epstein DL, deKater AW, et al: Ethacrynic acid increases facility of outflow in the human eye in vitro. Arch Ophthalmol 110:106, 1992.
176. Erickson-Lamy KA, Schroeder A, Epstein DL: Ethacrynic acid induces reversible shape and cytoskeletal changes in cultured cells. Invest Ophthalmol Vis Sci 33:2631, 1992.
177. Epstein DL, Schroeder A, deKater AW, et al: Ethacrynic acid uniquely disrupts cellular tubulin in trabecular and other endothelial cells. Invest Ophthalmol Vis Sci 32:1257, 1991.
178. Svedbergh B, Lütjen-Drecoll E, Oberr M, Kaufman PL: Cytochalasin B-induced structural changes in the anterior ocular segment of the cynomolgus monkey. Invest Ophthalmol Vis Sci 17:718, 1987.
179. Kaufman PL, Bárány EH: Cytochalasin B reversibly increases outflow facility in the eye of the cynomolgus monkey. Invest Ophthalmol Vis Sci 16:47, 1977.
180. Kaufman PL, Bill A, Bárány EH: Effect of cytochalasin B on conventional drainage of aqueous humor in the cynomolgus monkey: The ocular and cerebrospinal fluids. Exp Eye Res 25:411, 1977.
181. Kaufman PL, Erickson K: Cytochalasin B and D dose-outflow facility response relationships in the cynomolgus monkey. Invest Ophthalmol Vis Sci 23:646, 1982.
182. Fleckenstein A: History of calcium antagonists. Circ Res 52:13, 1983.
183. Braunwald E: Mechanisms of action of calcium-channel-blocking agents. N Engl J Med 307:1618, 1982.
184. Schnell D: Response of intraocular pressure in normal subjects and glaucoma patients to single and repeated doses of the coronary drug Adalat. *In* Lochner WEH, Lichtlen PR (eds): Second International Adalat Symposium. Berlin, Springer-Verlag, 1975.
185. Green K, Kim K: Papaverine and verapamil interaction with prostaglandin E_2 and Δ^9-tetrahydrocannabinol in the eye. Exp Eye Res 24:207, 1977.
186. Monica ML, Hesse RJ, Messerli FH: The effect of a calcium-channel blocking agent on intraocular pressure. Am J Ophthalmol 96:814, 1983.
187. Beatty JF, Krupin T, Nichols PG, et al: Elevation of intraocular pressure by calcium channel blockers. Arch Ophthalmol 102:1072, 1984.
188. Kelly SP, Walley TJ: Effect of the calcium antagonist nifedipine on intraocular pressure in normal subjects. Br J Ophthalmol 72:216, 1988.
189. Payne LJ, Slagle TM, Cheeks LT, et al: Effect of calcium channel blockers on intraocular pressure. Ophthalmic Res 22:337, 1990.
190. Suzuki R, Hanada M, Fujii H: Effects of orally administered β-adrenergic blockers and calcium-channel blockers on the intraocular pressure of patients with treated hypertension. Ann Ophthalmol 24:220, 1992.
191. Abelson MB, Gilgert CM, Smith LM: Sustained reduction of intraocular pressure in humans with the calcium channel blocker verapamil. Am J Ophthalmol 105:155, 1988.
192. Goyal JK, Khilnani G, Sharma DP, et al: The hypotensive effect of verapamil eye drops on ocular hypertension. Indian J Ophthalmol 37:176, 1989.
193. Netland PA, Erickson KA: Calcium channel blockers in glaucoma management. Ophthalmol Clin North Am 8:327, 1995.
194. Erickson KA, Schroeder AM, Netland PA: Verapamil increases outflow facility in the human eye. Exp Eye Res 61:565, 1995.
195. Camras CB, Podos SM: The role of endogenous prostaglandins in clinically-used and investigational glaucoma therapy. *In* Bito LZ, Stjernschantz J (eds): The Ocular Effects of Prostaglandins and Other Eicosanoids. New York, Alan R Liss, 1989.
196. Brubaker RF: The physiology of aqueous humor formation. *In* Drance SM, Neufeld AH (eds): Glaucoma. Applied Pharmacology in Medical Treatment. Orlando, FL, Grune & Stratton, 1984.
197. Melamed S, Teehasaened C, Epstein DL: Role of fibronectin in closure of YAG trabeculopuncture. Laser Light Ophthalmol 2:233, 1989.
198. Melamed S, Epstein DL: Alterations of aqueous humour outflow following argon laser trabeculoplasty in monkeys. Br J Ophthalmol 71:776, 1987.
199. Bylsma SS, Samples JR, Acott TS, Van Buskirk EM: Trabecular cell division after argon laser trabeculoplasty. Arch Ophthalmol 106:544, 1988.
200. Acott TS, Samples JR, Bradley JMB, et al: Trabecular repopulation by anterior trabecular meshwork cells after laser trabeculoplasty. Am J Ophthalmol 107:1, 1989.
201. Hedbys BO, Mishima S: The flow of water across the corneal layers. *In* Langham M (eds): The Cornea, Macromolecular Organization of a Connective Tissue. Baltimore, London: Johns Hopkins Press, 1969.
202. Renkin EM: Multiple pathways of capillary permeability. Circ Res 41:735, 1977.
203. Vargas CB, Vargas FF, Pribyle JG, Blackshear BL: Hydraulic conductivity of the endothelial and outer layers of rabbit aorta. Am J Physiol 236:H53, 1979.
204. Fels IG: Permeability of the anterior bovine lens capsule. Exp Eye Res 10:8, 1970.
205. Fatt I: Permeability of Descemet's membrane to water. Exp Eye Res 8:34, 1969.
206. Starita C, Hussain AA, Patmore A, Marshall J: Localization of the major site of resistance to fluid transport in Bruch's membrane. Invest Ophthalmol Vis Sci 38:762, 1997.
207. Robinson GB, Walton HA: Glomerular basement membrane as a compressible ultrafilter. Microvasc Res 38:36, 1989.
208. Levick JR: A two-dimensional morphyometry-based model of interstitial and transcapillary flow in rabbit synovium. Exp Physiol 76:905, 1991.
209. Mow VC, Holmes MH, Lai WM: Fluid transport and mechanical properties of articular cartilage: A review. J Biomech 17:377, 1984.
210. Fatt I: Hydraulic flow conductivity of the vitreous gel. Invest Ophthalmol Vis Sci 16:565, 1977.
211. Bill A, Lütjen-Drecoll E, Svedbergh B: Effects of intracameral Na_2 EDTA and EGTA on aqueous outflow routes in the monkey eye. Invest Ophthalmol Vis Sci 19:492, 1980.
212. Alvarado J, Yun A, Murphy C: Juxtacanalicular tissue in primary open angle glaucoma and in nonglaucomatous normals. Arch Ophthalmol 104:1517, 1986.